RD651
.N24
sec.8
f.29
1950
c.2

Library
National Institutes of Health
Bethesda 14, Maryland

D651
124
ct. 8, Fasc. 29
o. 2
v.l.c.

TUMORS OF THE ADRENAL

Howard T. Karsner, M. D.

LIBRARY
NATIONAL INSTITUTES OF HEALTH
APR 19 1957

ARMED FORCES INSTITUTE OF PATHOLOGY

TUMORS OF THE ADRENAL

Howard T. Karsner, M. D.

ARMED FORCES INSTITUTE OF PATHOLOGY

ATLAS OF TUMOR PATHOLOGY

Section VIII—Fascicle 29

TUMORS OF THE ADRENAL

by

Howard T. Karsner, M. D.
Medical Research Advisor, Bureau of Medicine and Surgery, U. S. Navy,
formerly Professor of Pathology, Western Reserve University

Published by the
ARMED FORCES INSTITUTE OF PATHOLOGY
Under the Auspices of the
SUBCOMMITTEE ON ONCOLOGY
of the
COMMITTEE ON PATHOLOGY
of the
NATIONAL RESEARCH COUNCIL
Washington, D. C.
1950

For sale by the American Registry of Pathology
Armed Forces Institute of Pathology
Washington 25, D. C. - Price $1.00

3393

ACKNOWLEDGMENTS

Grateful appreciation is expressed to Miss Theodora Bergsland for drawings and charts, and Mr. Benjamin W. Brownlow for aid in making photographs.

Illustrative material for this fascicle has been obtained through the kindness of the following physicians:

Dr. A. M. Hain	Figure 13.
Dr. F. H. Harvie	Figure 12.
Dr. R. S. Haukohl	Figures 32, 33.
Dr. Eleanor M. Humphreys	Figure 42.
Dr. James Joelson	Figures 8, 9, 10, 14, 15, 16, 17, 18, 19, 35, 37, 40, 41, and Plates I, II, III.
Dr. James Lynch	Figure 11.
Dr. J. E. McClelland	Figure 34.
Dr. H. R. Trattner	Figure 7.
Dr. John Williams	Figure 36.

Copyright permissions for the use of illustrations have been granted by these publishers:

American Registry of Pathology—Figure 42
Atlas of Genitourinary Pathology p. 213, 1946.

Oliver & Boyd, Ltd.—Figure 13
Journal of Pathology and Bacteriology, Vol. LIX, 280, 1947.

Rockefeller Institute for Medical Research—Figure 28
Journal of Experimental Medicine, Vol. 12, 560–561, 1910.

Howard T. Karsner.

ATLAS OF TUMOR PATHOLOGY

Sponsored and Supported

by

AMERICAN CANCER SOCIETY

ANNA FULLER FUND

ARMED FORCES INSTITUTE OF PATHOLOGY

JANE COFFIN CHILDS MEMORIAL FUND FOR MEDICAL RESEARCH

NATIONAL CANCER INSTITUTE, U.S. PUBLIC HEALTH SERVICE

UNITED STATES VETERANS ADMINISTRATION

TUMORS OF THE ADRENAL

TABLE OF CONTENTS

	Page No.
Introduction	5
TUMOR-LIKE LESIONS	6
Cortical Nodules	6
Figs. 1–5	
Myelolipoma	7
Fig. 6	
CORTICAL TUMORS	13
Adenoma	13
Figs. 8, 9, 11, 13, 15, 16, 18, 20. Plates I, II	
Carcinoma	18
Figs. 7, 10, 12, 14, 17, 19, 21. Plate III	
MEDULLARY TUMORS	27
Fig. 22	
Sympathicogonioma	27
Figs. 23–30	
Sympathicoblastoma	30
Fig. 34	
Ganglioneuroma	30
Fig. 31	
Malignant Ganglioneuroma	31
Figs. 32, 33	
Pheochromocytoma	41
Figs. 35–42. Plates IV, V	
Pheochromoblastoma	46
Fig. 14	
MELANOMA	55
Fig. 41	
SECONDARY TUMORS	59
Figs. 43–47	

TUMORS OF THE ADRENAL

INTRODUCTION

True neoplasms of the adrenal glands are infrequent or rare. They include (1) those derived from cells peculiar to the adrenal, and (2) those derived from tissues in the adrenal not peculiar to that structure and common to other situations. The former are the lesions considered especially in this fascicle.

Of the latter, fibroma, myoma, neurofibroma, and lipoma are infrequent incidental findings. The so-called "osteoma" is probably a metaplasia following inflammation or hemorrhage. Both hemangioma and lymphangioma have been reported. Two "hemangioblastomas" have been reported (Marten and Meyer, Menon and Annamalai). So-called "cysts" of the adrenal are apparently either pseudocysts resulting from cystic degeneration of hematomas or adenomas, or are dilated angiomatous cavities (Reimann and Guyton). The latter are more frequent in the lymphangioma where the cavities are frequently multilocular.

The spindle and giant cell sarcomas of the older literature were probably anaplastic carcinomas. The "round cell" sarcomas would undoubtedly be classified today as sympathicogoniomas. In the last decade no verified cases of lymphosarcoma confined to the adrenal have been found. The fibrosarcoma described by Cran appears to be a true sarcoma, and myxosarcoma has been reported. Neoplasms should be distinguished from nodular lesions which resemble neoplasms.

References

Cran, B. S. Fibrosarcoma of the suprarenal gland. Brit. M. J., 2:1018–1019, 1933.

Marten, M. E., and Meyer, L. M. Hemangioblastoma of the adrenal. Am. J. Cancer, 40:485–487, 1940.

Menon, T. B., and Annamalai, D. R. A haemangioblastoma of the adrenal gland. J. Path. & Bact., 39:591–594, 1934.

Reimann, D. L., and Guyton, W. L. Cysts of the adrenal gland with case report. Am. J. Path., 23:479–484, 1947.

TUMOR-LIKE LESIONS

Hamartoma is the name given to a tumor-like malformation in which there is an abnormal arrangement and redundancy of cells and structures in themselves natural to the part or organ. A hamartoma may become a neoplasm. Lymphangioma and hemangioma are rare in the adrenal, but appear like similar lesions elsewhere. The cortical nodule is a tumor-like arrangement of cells like those of the adrenal cortex and is a hamartoma. The exact classification of the myelolipoma is not certain. If bone marrow is a natural component of adrenal, it is a hamartoma. However, if it is a tumor-like nodule arising from heterotopic inclusion of bone marrow, it is a choristoma. The pigmented nevus of the skin is usually classified as a progonoma because of resemblance to dermal organs of primitive species. However, if the nevus or the melanoma is primary in the adrenal, the term progonoma is not justified and the lesion is primarily a hamartoma and then a neoplasm.

Cortical Nodules. Synonyms and Related Terms: Noduli substantiae corticalis suprarenalis (Lat.); benign adenoma; cortical adenoma. When multiple and numerous, struma suprarenalis. When in other parts of the body, Marchand nodule, accessory adrenal, ectopic adrenal, or adrenal rest.

DEFINITION. Cortical nodules are spherical, well defined, usually encapsulated masses of cells like those of the adrenal cortex. They occur in the cortex, capsule, or apparently in the periadrenal fat.

ORIGIN. This is probably the result of pinching off of the cortex either during embryonal and fetal development, or during subsequent growth, particularly in the fourth and fifth decades when the adrenal may be an active participant in sexual involution.

CLINICAL FEATURES. None. Cortical nodules are an incidental observation in about one-third of the autopsies.

DESCRIPTION. The condition is usually bilateral. The nodules are usually spherical and vary in size within the same specimen. The diameter ranges from less than a millimeter to 3 or 4 centimeters. They are often multiple and usually small in number. The nodules are yellow and of about the same consistency as the adrenal. They are well-defined with a more or less distinct capsule. Infrequently, nonencapsulated forms occur. Serial sections of several specimens have demonstrated that those in the periadrenal fat are attached to the cortex by a pedicle of cortical cells or of connective tissues (figs. 1, 2, 3, 4, 5).

MICROSCOPIC. The capsule is of variable thickness in different nodules. It is composed of poorly vascularized, mature collagenous tissue. The cells of the nodule are arranged like those of the zona glomerulosa, sometimes with additional cords like the zona fasciculata, but only rarely like the zona reticularis. With great rarity, there is a semblance of acinus formation. The cells are about the same size as those of the adrenal cortex. The nucleus is vesicular. Multinucleated cells are rare. The cytoplasm is vesicular. The lipid content is about the same as in the neighboring cortex. The reticular zone cells may contain brown lipofuscin. When lipids are reduced in amount in the cortex, they usually remain in the nodules. Connective tissue stroma and capillaries are like those of the adrenal cortex.

DIFFERENTIAL DIAGNOSIS. There is no sharp line of distinction between a cortical nodule and a cortical adenoma. However, the cortical nodule is usually multiple and the adenoma single. The adenoma is usually larger than the nodule and often without the regularity of cellular arrangement of the nodule. It is suspected that a nodule may give rise to an adenoma, and, if that be true, may, through transformation of the nodule, be the ultimate source of a cortical carcinoma.

Reference

Nelson, A. A. Accessory adrenal cortical tissue. Arch. Path., 27:955–965, 1939.

Myelolipoma. Synonyms and Related Terms: Myelolipoma (Lat.); ectopic bone marrow; metaplastic bone marrow.

DEFINITION. This is a tumor-like mass of fatty tissue, usually beginning in the medulla but sometimes in the cortex, and composed of fat and cells like those of bone marrow.

ORIGIN. Three theories of origin are proposed. (1) Inclusion of embryonal rests, presumably of primitive mesenchyme which is the first hematopoietic tissue; this may subsequently produce nodules of marrow and even of bone. (2) Embolism of marrow cells through the blood stream. (3) Metaplasia of cells, especially reticulo-endothelial cells of the blood capillaries and sinuses.

CLINICAL FEATURES. None. This is an infrequent incidental observation at autopsy. It is not a manifestation of extramedullary hematopoiesis in blood dyscrasias.

DESCRIPTION. Usually, there is a single mass in one adrenal, but occasionally a single mass is also present in the opposite adrenal. It is spherical, ellipsoidal, or ovoid, with a dimension of from a few millimeters to 5 or 6 centimeters. The outline is fairly sharp, but the lesion is not encapsulated, except perhaps in rare instances. The color varies from pale yellow to bright yellow and from reddish brown to brown. The consistency is moderately firm. Hard foci of calcification or ossification are rarely observed.

MICROSCOPIC. The lesion is well defined and surrounded by adrenal tissue which is not likely to be compressed (fig. 6). Usually the principal component is fat in the form of large single vacuoles. Only rarely do immature fat cells with numerous small fat droplets occur. Between the fat cells are cells like those of bone marrow. These may be in small foci which require careful search for identification, or the marrow cells may be in great abundance. There is much variation from lesion to lesion. In some instances, cells of the granulocytic series preponderate, while elsewhere the principal cells are of the erythrocytic series. Lymphocytes are often present and occasionally megakaryocytes. Mitotic figures have not been reported. The lesion is usually rich in capillaries. Fibrous stroma is usually scanty but may be abundant. In none of our cases has a capsule been present.

DIFFERENTIAL DIAGNOSIS. The rare adrenal lipoma is not encapsulated and is not well vascularized. It is devoid of cells of bone marrow. It is possible that growth of bone may give the appearance of osteoma, but marrow is also present.

Reference

Giffen, H. K. Myelolipoma of the adrenals. Report of seven cases. Am. J. Path., 23: 613–625, 1947.

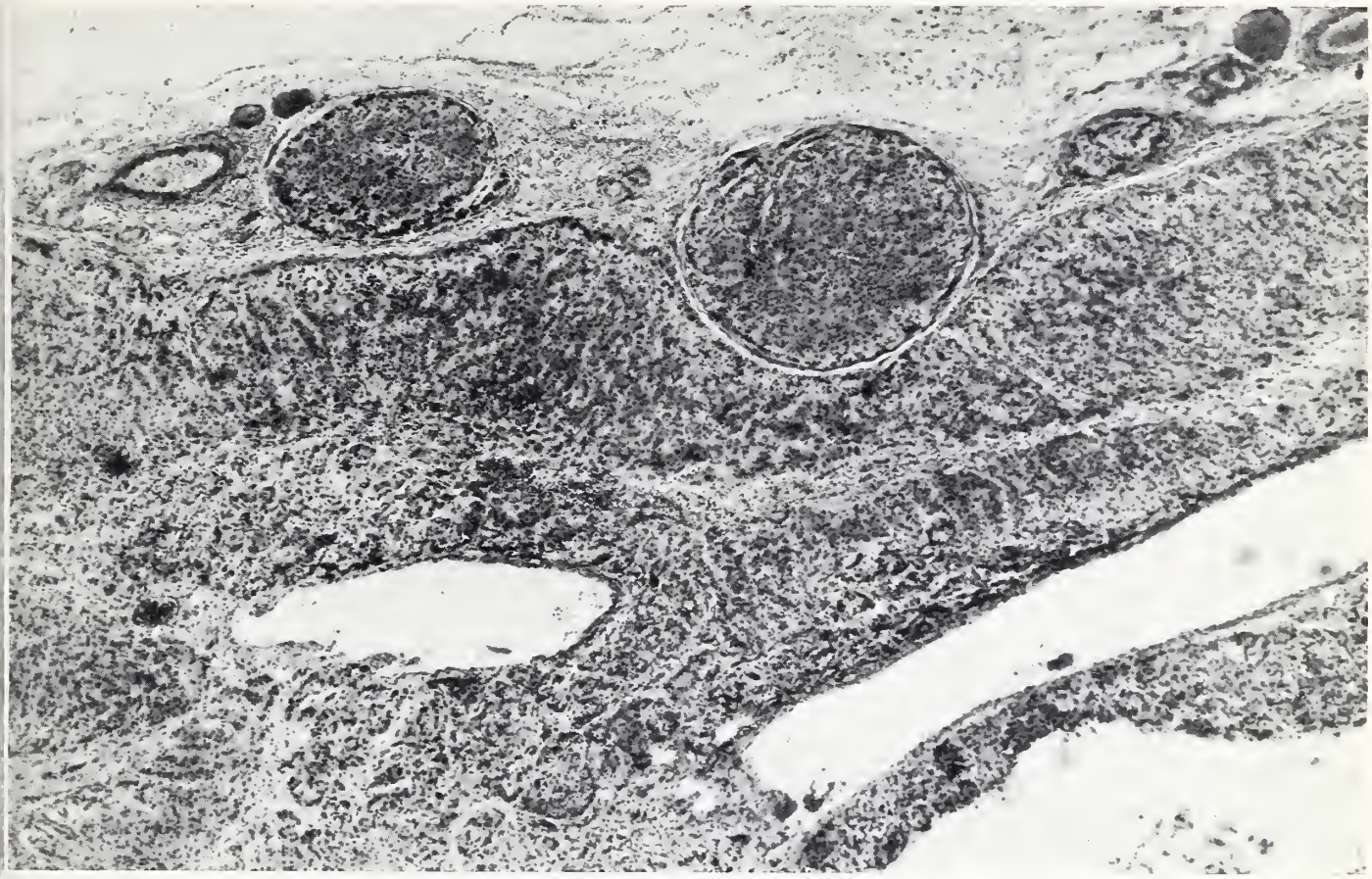

Figure 1. Cortical nodules in and outside capsule of adrenal. × 53. A. F. I. P. Neg. Acc. No. 218755–1.

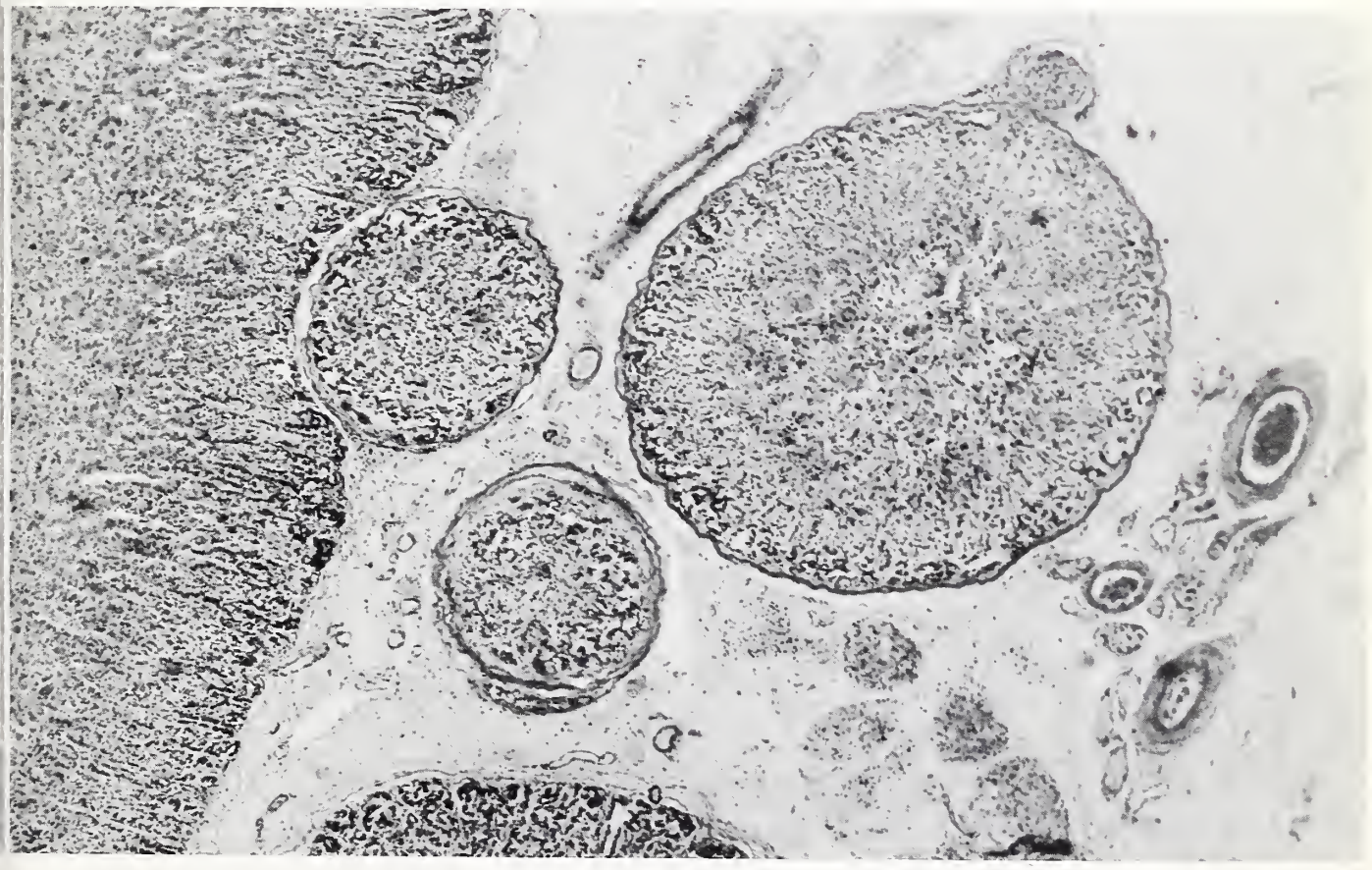

Figure 2. Cortical nodules outside capsule and in periadrenal fat—only apparently isolated from cortex. × 53. A. F. I. P. Neg. Acc. No. 218755–2.

Figure 3. Cortical nodule in cortex to show type and arrangement of cells. Delicate capsule. × 213. A. F. I. P. Neg. Acc. No. 218755–3.

Figure 4. Cortical nodule in cortex. Not encapsulated but with compression of surrounding cortical tissue. × ca. 100. A. F. I. P. Neg. Acc. No. 121291–1.

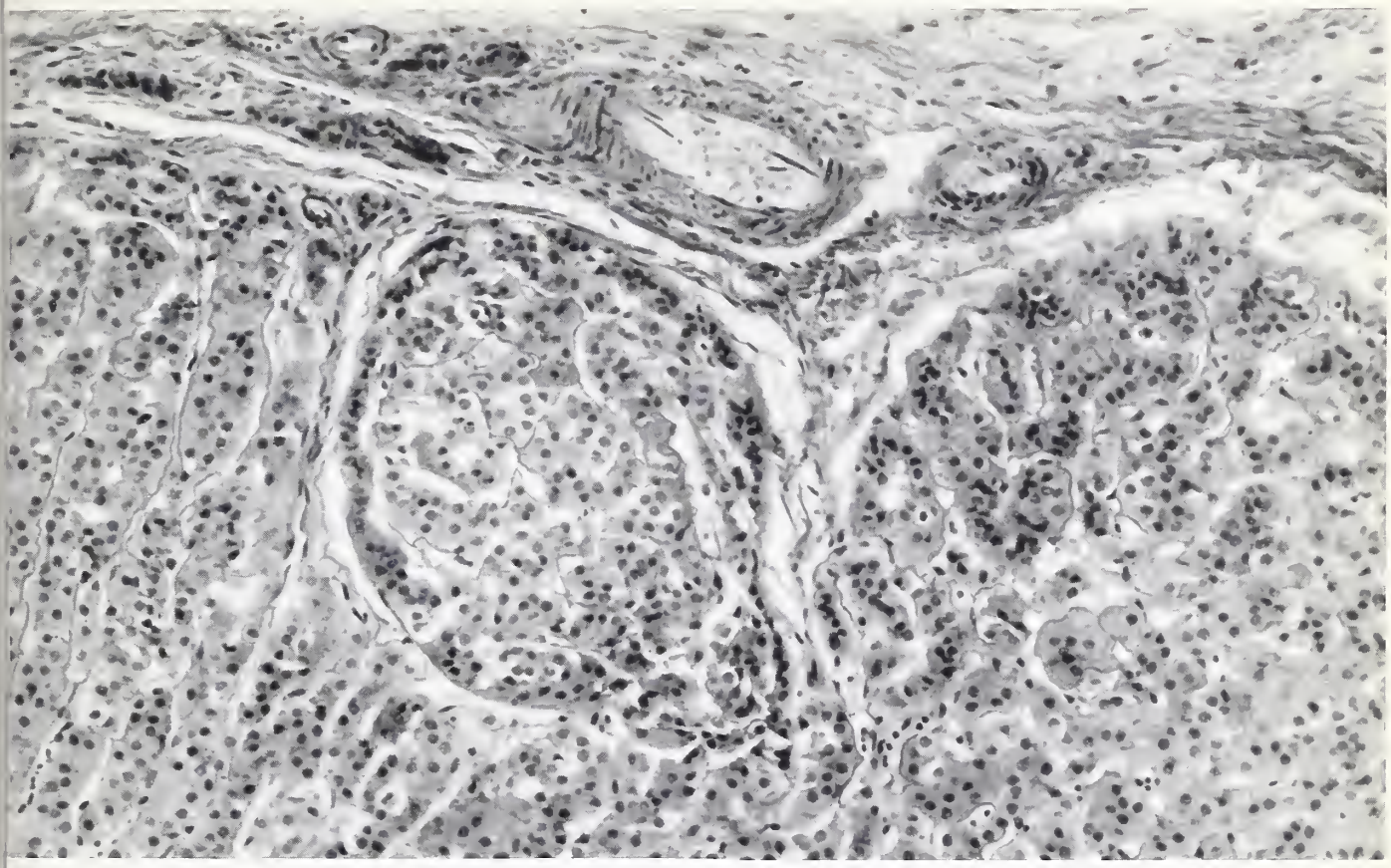

Fig. 3

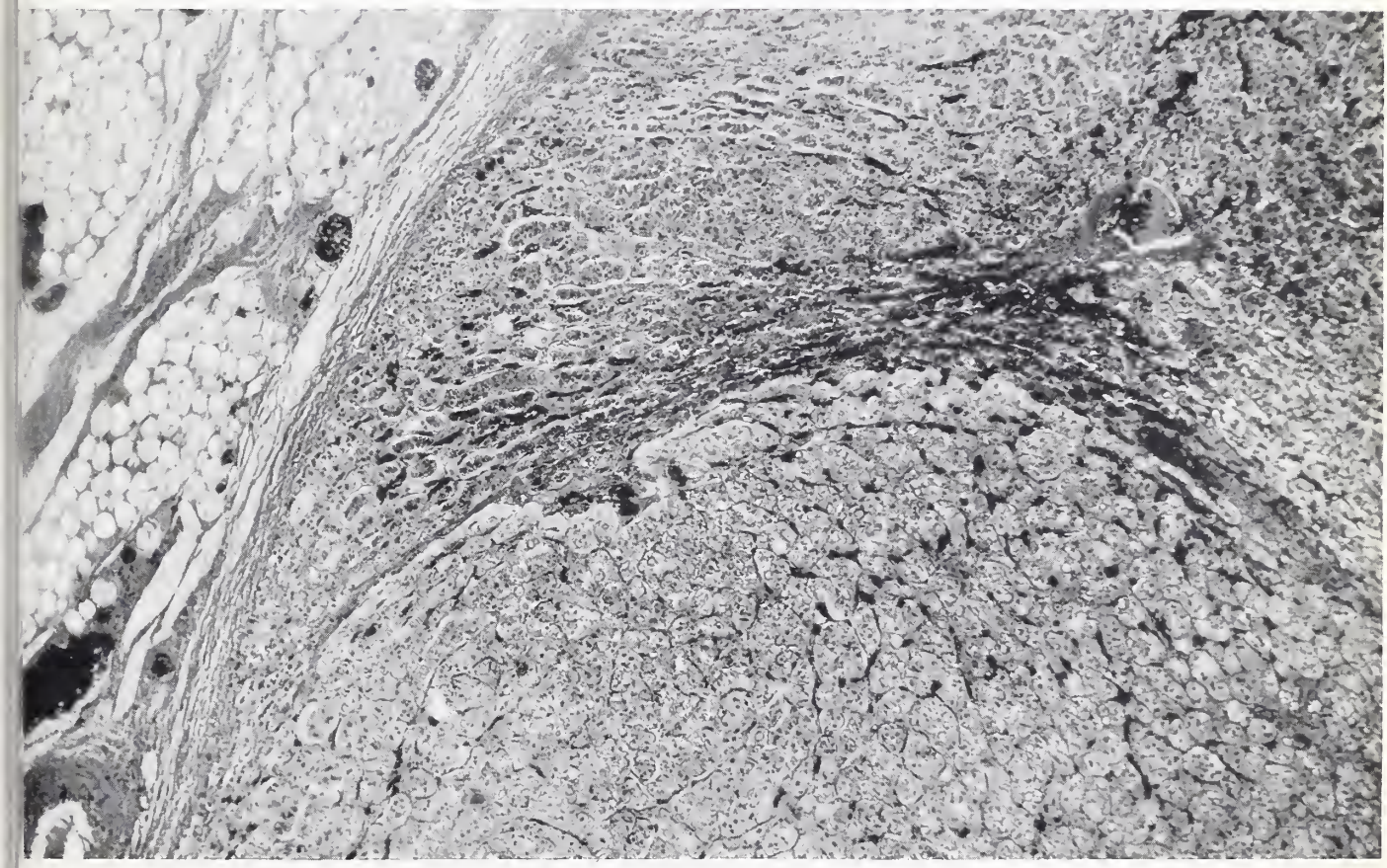

Fig. 4

Figure 5. Large nonencapsulated cortical nodule. At left, below, portion of encapsulated nodule. Might be named struma suprarenalis. × ca. 10. A. F. I. P. Neg. Acc. No. 121291–2.

Figure 6. Myelolipoma of adrenal. Fat cells and myeloid cells, principally of the granulocyte series. Section from cortex. No capsule and no compression of adrenal cortical cells. × 210. A. F. I. P. Neg. Acc. No. 218755–4.

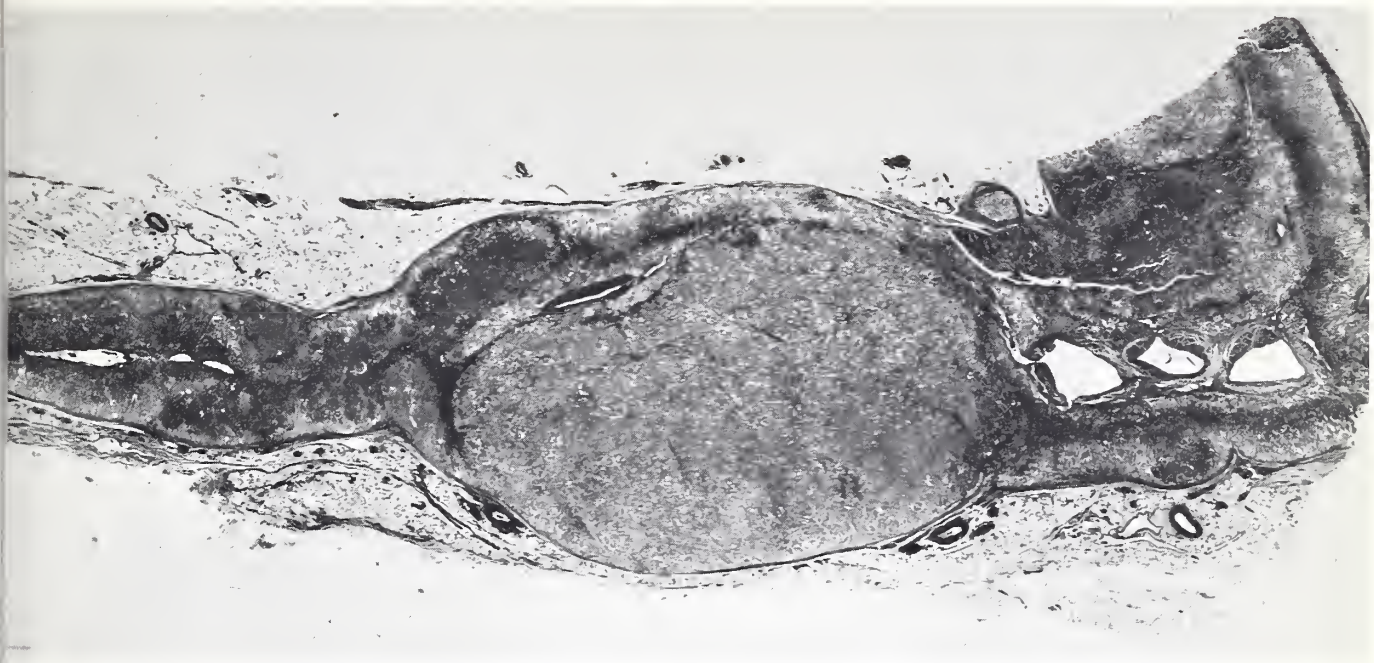

Fig. 5

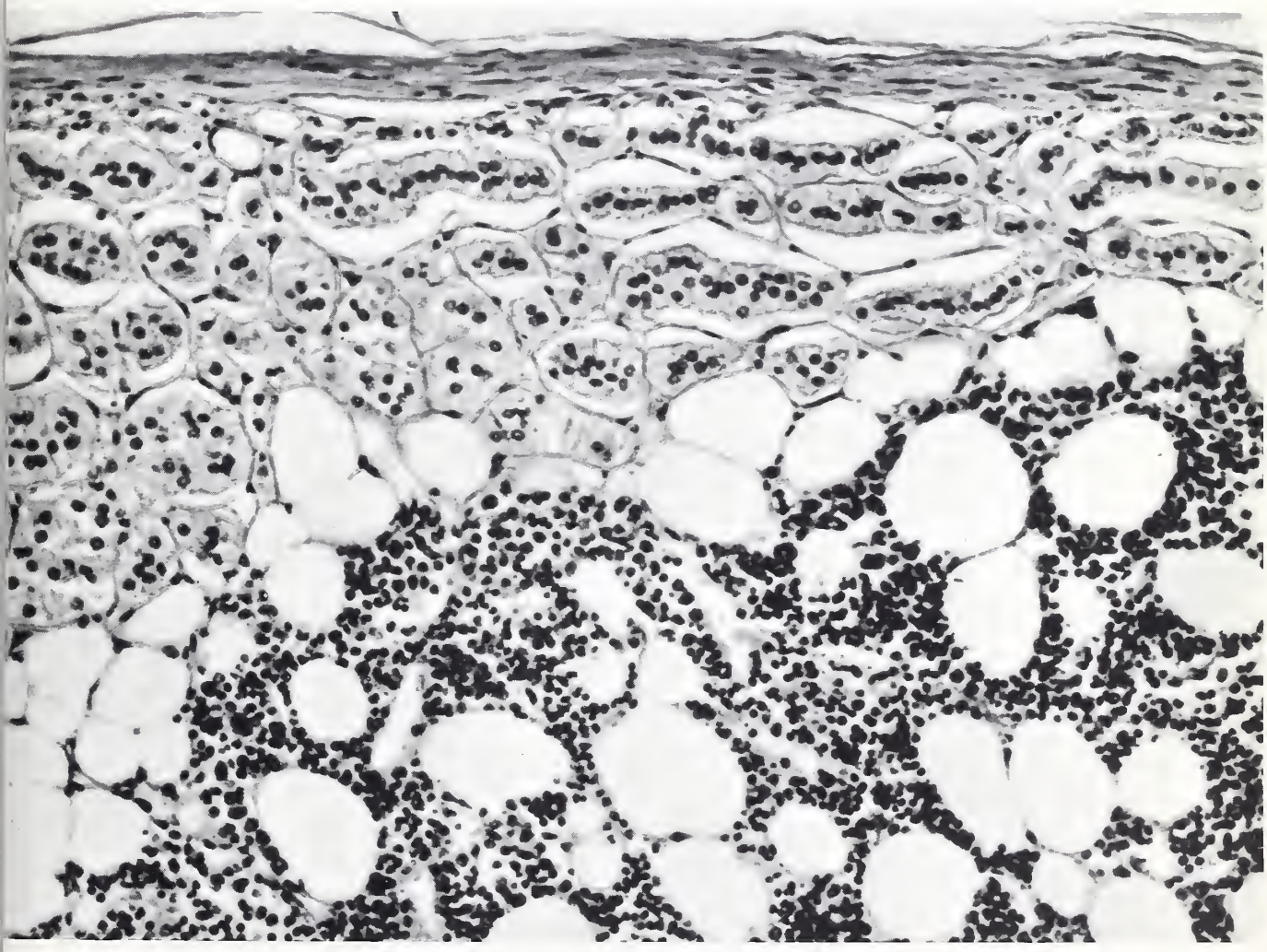

Fig. 6

Figure 7. Three-year-old girl, admitted for acne. "Infant Hercules" musculature. Cortical tumor of left adrenal, which proved to be carcinomatous. Death from hemorrhage at operation. Autopsy disclosed metastases in lung. (Patient of Dr. H. R. Trattner.) A. F. I. P. Neg. Acc. No. 218755–5.

Figure 8. Young woman, 22 years old. Menarche at 13, amenorrhea since 16. Benign tumor of right adrenal. Has been well for 11 years. Reversal of symptoms and signs after removal of tumor, except for persistence of a slight degree of hirsutism. Has had several successful pregnancies. See figures 9, 15, 16, 18, and plates I and II. (Patient of Dr. James Joelson.) A. F. I. P. Neg. Acc. No. 218755–6.

Figure 9. Cross section of cortical adenoma from patient shown in figure 8. Completely encapsulated but with adrenal cortex at position 9 to 12 o'clock. Lobulated and with small foci of necrosis. Cross section, bulging and mottled yellow and brown. A. F. I. P. Neg. Acc. No. 218755–7.

Fig. 7

Fig. 8

Fig. 9

TUMOR-LIKE LESIONS

PROFESSIONAL NOTES AND FINDINGS

HOMOLOGOUS TUMORS

CORTICAL TUMORS

Cortical Adenoma. Synonyms and Related Terms: Adenoma substantiae corticalis suprarenalis (Lat.); adenoma; adrenal hypernephroma; functioning cortical tumor; granular cell tumor of adrenal cortex (Cahill).

DEFINITION. Cortical adenomas are benign encapsulated neoplasms composed principally of cells resembling those of the adrenal cortex. They are usually single and unilateral, of variable size, but sometimes exceedingly large. The term "adenoma" is used because of the origin in a gland; only rarely are acinic structures evident.

ORIGIN. There is no proof that the tumor is derived from mature cortical cells. The variable cellular picture can be explained by an irregular progression of the usual change from the zona glomerulosa through the fasciculata to the reticularis. However, the tumor may originate in primitive cells which have the potentiality of this progression. It is also possible, but not proved, that a cortical nodule may give rise to an adenoma.

CLINICAL FEATURES. In early life, the lesion is more frequent in females, but this difference is not so great in adult life. The tumor may occur from infancy to late adult life, but is most frequent in childhood and adolescence. Functional alterations are more common in early than in later life and may be absent in adults. The clinical manifestations depend on (1) the size and position of the tumor, (2) the production of hormones by the tumor, and (3) the metabolic disturbances incident to hormonal activity.

The tumor may be large enough to produce bulging of the flank or general enlargement of the abdomen. Tumors of lesser size may be palpable. Pain is infrequent.

HORMONAL PHENOMENA are included in the term adrenogenital syndrome and are conditioned by age and sex. Adrenal cortical dysfunction can occur in benign or malignant tumors and may also be present without neoplasia, due either to hyperplasia, or to hyperfunction of an organ, the size of which is not necessarily increased. Developing in utero, the tumor may be accompanied by female pseudohermaphroditism, but more often there is only cortical hyperplasia in these patients. The sexual properties of the adrenal cortex are indicated by virilism of girls, somatic sexual precocity of boys, and, rarely, feminism of men and boys.

In young patients of either sex, bones may grow rapidly with increased length of long bones, advanced bone age terminating in premature closure of the epiphyses. Such arrest of the growth of the long bones while the trunk continues to increase in length produces a resemblance to achondroplastic dwarfism. Premature dentition also occurs. Slight degrees of persistent or periodic hypertension may occur but without those symptoms attributed to excess release of epinephrine which occur in cases of pheochromocytoma.

Virilization of females varies with age. In children, secondary sexual characters develop, including enlargement of mammary glands, mons pubis, labia and clitoris, growth of hair on pubis and axillae and sometimes on face, deepening of voice, advanced bone age, and acceleration of growth (figs. 7, 10, 11, 12, 13). Between menarche and menopause, especially near the former, fat distribution is like that of males with broad shoulders and narrow hips, small breasts, conspicuous hirsutism (fig. 8) of the body, male type of escutcheon, deep voice, seeming enlargement of larynx, large clitoris sometimes erectile, and amenorrhea or reduced menstrual flow. Libido may be normal, reduced, or inverted. When hormonal activity occurs in the postmenstrual period, the principal changes are hirsutism, enlarged clitoris, deep voice, and sometimes minor psychic disturbances. Of the 70 cases (53 girls and 17 boys) which were collected by Wilkins, changes resembled those of Cushing's syndrome in 41 percent (22 cases) of girls and in 12 percent (2 cases) of boys.

In boys there may be precocious development of sexual characters, principally somatic. There is vigorous growth of hair on the head, face, and body, accompanied by macrogenitosomia praecox, and a deep voice (figs. 10, 11, 12, 13). Erections occur and emissions have been reported. Broster and Patterson report that in heterosexual virilism the patient has two adrenal glands, but in isosexual virilism there may be complete absence of one adrenal.

Feminization of males has been reported in 12 instances. All were in patients between 26 and 44 years of age except one at 5 years and one at 15 years. The usual clinical manifestation is gynecomastia. In some there is also atrophy of testes, and in some a reduction of libido and potency. As might be expected with cortical tumors of later life, many of these proved to be carcinomas.

Acne is frequent in boys and girls. Muscular development of the "infant Hercules" types is not frequent and is more often observed in girls than boys (figs. 7, 10).

Urinary hormonal assays do not give constant results. In virilized females, androgens are usually increased in amounts. The 17-ketosteroids may be as much as 50 times the normal. However, the assays may give figures in the upper range of normal. Sometimes the amount of pregnanediol is also increased, indicative of production of progesterone by the adrenal tumor. Probably the most significant androgen is dehydroisoandrosterone. When it

and associated steroids are present in excess, the diagnosis of cortical tumor is assured by the analysis of urinary steroids. Broster and Patterson describe a simplified test of these steroids. The test is of considerable value in distinguishing those cases of Cushing's syndrome associated with cortical hyperplasia of the adrenal, with or without basophilic adenoma of the pituitary, from those in which there is adrenal cortical tumor. In the hyperplasias the dehydroisoandrosterone is not in excess, whereas in the cortical tumors it is increased.

The figures for estrogens in virilized cases are variable, but approximately within normal range. In the few assayed cases of feminization, the estrogen output is variable, but in a few cases there has been a large increase in output of estrogens together with a slight increase of androgens.

Metabolic changes reported include those of fat, carbohydrate, and protein. Obesity is rare except in those cases with Cushing's syndrome. Obesity should not be confused with enlargement of abdomen by tumor or protrusion because of osteoporosis. Glycosuria and diabetes occur with adrenal cortical tumors but are noted especially in those cases with Cushing's syndrome. Evidence implicates adrenal steroids.

Patients with cortical hyperfunction may have a negative or a positive nitrogen balance. This appears to account in part for the marked clinical variations, particularly in that some cases show muscular atrophy and others hypertrophy (figs. 12, 13). Albright * explains the alterations in nitrogen balance as due to variability in production of "S" (sugar) and "N" (nitrogen) steroid hormones. The "S" hormone, being "anti-anabolic" inhibits synthesis of tissue and when present in excess, as in Cushing's syndrome, results in a negative nitrogen balance, cessation of epiphyseal growth, and neutralization of the pituitary growth hormone. The low level of tissue growth is little changed by high protein diet. In addition, the 11-ketosteroid urinary excretion is increased, and hyperglycemia may be present. The "N" hormone action is similar to that of testosterone and stimulates tissue growth, thereby producing a positive balance of nitrogen, calcium, phosphorus, and potassium, as well as increased growth, excessive sexual and somatic development, and marked virilism. It also causes an increase of 17-ketosteroid excretion.

Cortical extracts of the desoxycorticosterone type also play a role in the maintenance of water-sodium level of the body. Destruction of cortical tissue, whether from Addison's disease, hemorrhage, bilateral tumors, or tumor with contralateral atrophy or other causes, results in low plasma sodium chloride, dehydration, hemoconcentration, low blood pressure, and shock. Conversely, when desoxycorticosterone is increased, as occurs in some of the functioning cortical tumors (Conn), the sodium and chloride content of plasma, urine and sweat is increased, and blood pressure tends to rise. In general the potassium level is inverse to, but does not closely parallel, that of sodium.

---

*Albright, Fuller, Personal Communication.

Cortical functions can be divided into three classes: (1) Sex hormones; (2) steroids which affect the protein and carbohydrate metabolism, the "N" and "S" factors of Albright; (3) steroids of desoxycorticosterone type which affect the sodium chloride-water metabolism. The extent of normal variations in these functions is not clearly defined. Functioning cortical tumors may involve any one or all of the factors in varying degrees. The histological structure of the tumor, whether adenoma or carcinoma, gives little clue to its function or lack of function.

Clinical diagnosis depends on studies of hormonal and metabolic changes, as indicated above, and on methods for localization of the tumor. In nonhormonal cases, tumor mass or pain, or both, may be found. In either event, other diagnostic measures are pursued. Roentgenograms may disclose a soft tissue mass, sometimes with foci of calcification. Pyelograms, especially retrograde, may disclose downward displacement of the kidney and backward displacement of its upper pole (fig. 14). Oxygen insufflation may disclose the site and size of the tumor (fig. 15), but is not without minor hazard of gaseous embolism. Exploratory operation may be necessary. If so, it should be by the lumbar route so that both adrenals can be examined.

DESCRIPTION. The tumor may be spherical, ovoid, or ellipsoid. It attains a dimension of several centimeters and weighs from 100 to 200 grams. Much greater weights have been reported, up to 1,990 grams, and even to 4,200 grams. The larger tumors are more frequent in adults than in younger patients. The tumor is smooth in outline and encapsulated, brown or yellow, and moderately firm. The cross section is moist, bulges, is brown and yellow, bleeds moderately, and is often somewhat lobulated. It may be mottled by foci of necrosis and hemorrhage. Hyaline scars with hemosiderin pigment may occur at sites of old hemorrhage. Cysts are not frequent but may be large (plate I). They are usually smooth walled and contain brown, watery fluid or clotted blood. They probably result from hemorrhage. The capsule of the tumor is fibrous, usually thin, and intact. Even in the gross, segments of adrenal cortex are visible as narrow, yellow bands about the capsule (fig. 9).

MICROSCOPIC. The thin capsule, which entirely surrounds the tumor, is composed of mature, collagenous connective tissue. The surrounding adrenal tissue is usually but not always compressed. The tumor is composed almost entirely of cells which resemble those of the adrenal cortex. Extensive portions are composed of large cells with small, vesicular nuclei. The cytoplasm is vesicular and some of this is due to its lipid content (figs. 16, 18). However, other fields are composed of cells of the same morphology but with little or no lipid in the cytoplasm. In addition, there may be many cells which are elongated, sometimes of spindle form (fig. 20), and with dense cytoplasm. There may be cells which resemble the oncocytes of Hamperl; i. e., tumor epithelium with voluminous acidophilic granular cytoplasm and no significant nuclear change.

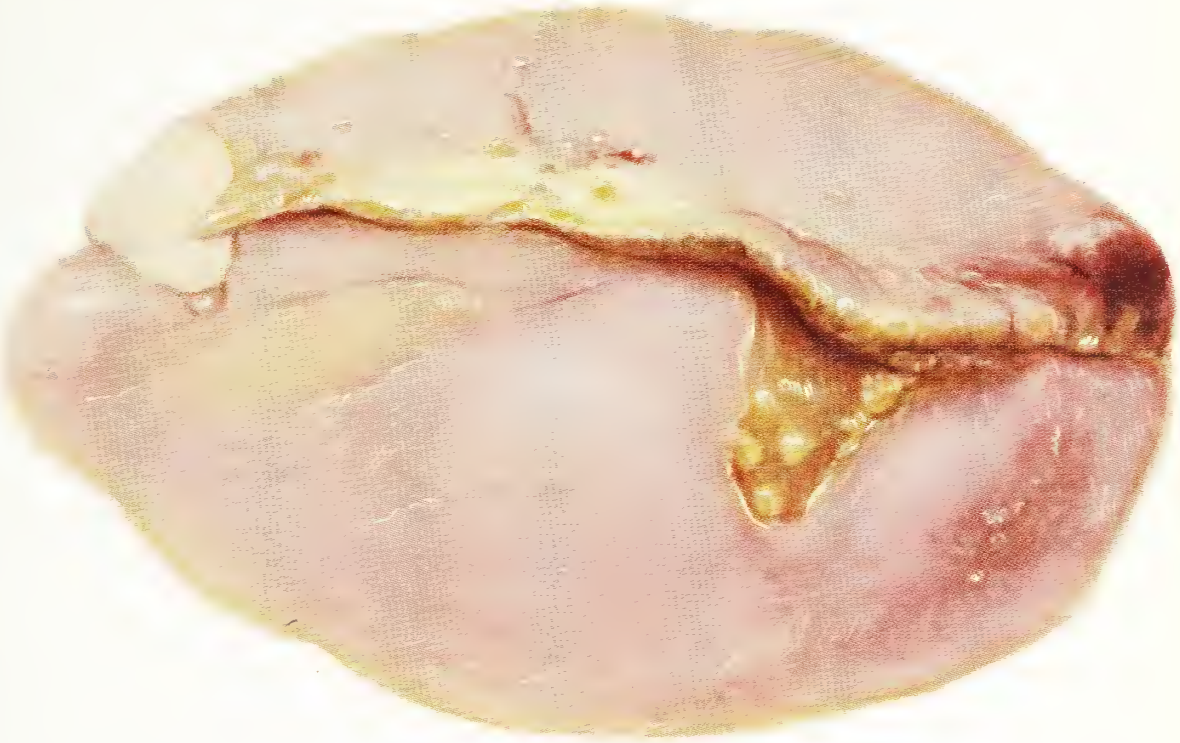

Plate I. A. Drawing of the outer surface of cortical adenoma of adrenal. Note bright yellow of cortex of the gland. A. F. I. P. Neg. Acc. No. 218755–C3.

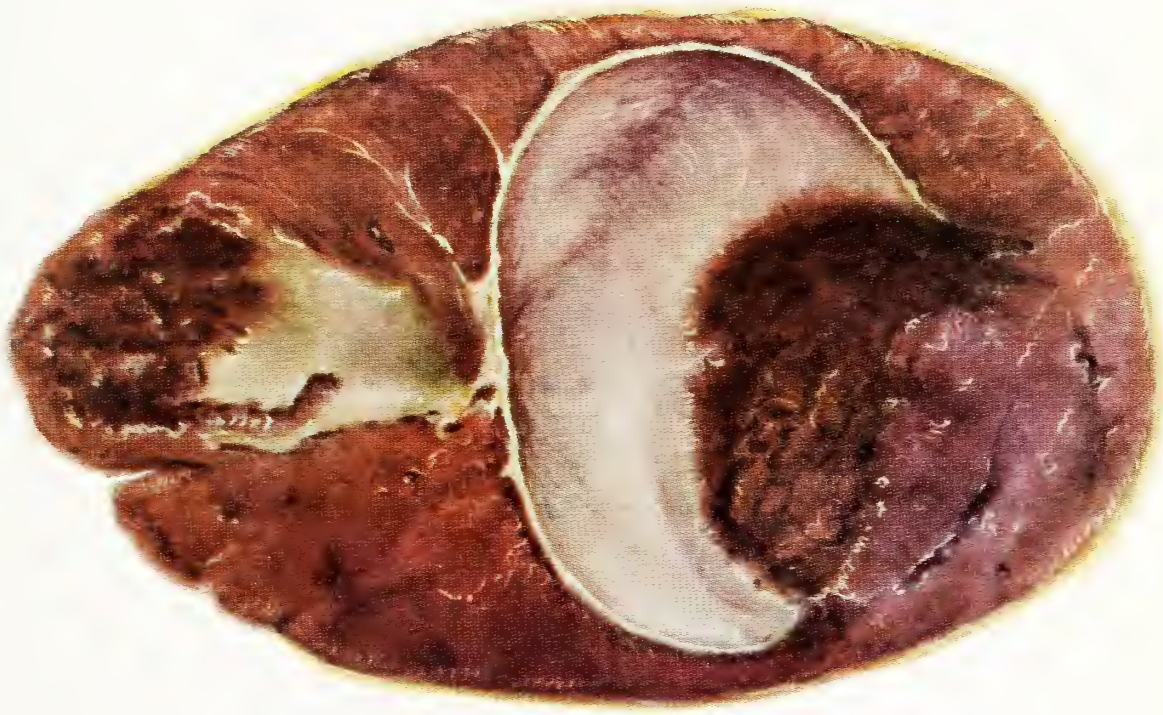

Plate I. B. Drawing of cross section of tumor illustrated in A. The brown neoplastic tissue was soft, bulging, and friable. The large cyst is partly limited by fibrous connective tissue. The content was dark brown, liquefied and finely granular. A. F. I. P. Neg. Acc. No. 218755–C4.

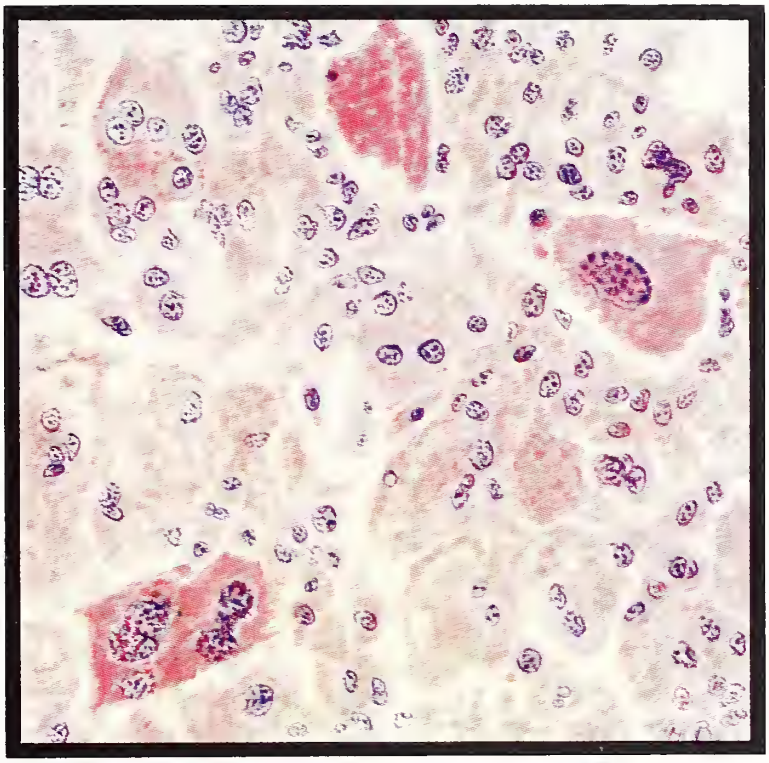

Plate II. Microdrawing of fuchsinophile cells in virilizing benign cortical adenoma. Patient shown in figure 8. Text indicates that these cells are not diagnostic of virilizing function. A. F. I. P. Neg. Acc. No. 218755–C5.

Thus, pleomorphism and lack of uniformity of size are common. Cells may also be multinucleated (fig. 16). Mitotic figures are infrequent and of normal configuration. Polygonal, pigmented cells like those of the zona reticularis are infrequent. Special stains demonstrate lipids and glycogen in variable amounts.

For the most part the cells are arranged in clusters which resemble those of the zona glomerulosa. However, the clusters may vary greatly in size and outline. Furthermore, even at the periphery of the tumor, the arrangement may be like that of the zona fasciculata (fig. 18). The cells in the individual clusters are generally of the same type, rich or poor in lipid with intervening delicate fibrous septa and blood vessels. Arteries and veins are not numerous. Even large channels are prevailingly capillary in type with only an endothelial wall. This predisposes to the hemorrhage, necrosis, hemosiderin deposits, and scarring noted in the gross description. Except for scars, the fibrous stroma and reticulum are scanty.

Special staining techniques have been devised in an attempt to characterize the functioning tumors. Broster and Vines described the fuchsinophile cell demonstrated by the use of ponceau fuchsin, cell which they thought indicated virilizing function (plate II). Similar cells have been found in apparently normal adrenals, in cortical nodules, in nonfunctioning adenomas, among sympathetic ganglion cells, in smooth muscle of arteries, and elsewhere. We have demonstrated them in the adrenal cortex, in pheochromocytomas, and in cortical nodules. Wilkins was unable to differentiate a virilizing and a feminizing tumor on this or any other basis. The fuchsinophile cell cannot be regarded as indicative of sexual function. Goormaghtigh described cells in masculinizing tumors in which siderophilic and acidophlic granules were found in the poles. He found golden yellow pigment granules in both intracellular and extracellular positions in one case of feminizing adenoma. These observations require confirmation.

Weber and Menten give details of a virilizing cortical tumor, in which cellular changes paralleled the secretory changes observed in the normal adrenal. These, however, were in fresh material and disappeared after prolonged fixation. The material was demonstrated by ponceau fuchsin and sudan IV but was removed by fat solvents. They assumed that these secretory globules are associated with the formation of hormones, but this is not positively established.

DIFFERENTIAL DIAGNOSIS. The adenoma is single, exceeding the normal adrenal gland in size. It has a complex cellular arrangement. In these respects it differs from the cortical nodule. It differs from the carcinoma in that the capsule is not invaded or penetrated, although there are exceedingly rare cases of metastasis without invasion of the capsule. Of special importance is the fact that it can only be certainly distinguished from the pheochromocytoma by chromation of the tissue to demonstrate absence of chromaffin cells (plate

V), or by such a special method as Vulpian's ferric chloride reaction wherein a green color is produced. This reaction is not specific, but is apparently due to the catechol ring present in epinephrine and other organic compounds.

TREATMENT. The only recourse is surgical removal, preferably by lumbar route in case of smaller tumors and transperitoneally with larger tumors. If there is any doubt as to which side is affected, exploration of both sides by lumbar route may be necessary. If the site of the tumor is certainly established, bilateral incisions are not advised because involvement of both adrenals by functioning tumors, if it occurs at all, is exceedingly rare and removal of both adrenals would be disastrous. Results are excellent except that some of the hirsutism may remain. Operative and postoperative acute adrenal insufficiency sometimes supervenes because the opposite adrenal may become atrophic.

Cortical Carcinoma. Synonyms and Related Terms: Carcinoma substantiae corticalis suprarenalis (Lat.); adrenal hypernephroma malignum; alveolar sarcoma; angiosarcoma; hypernephroid tumor; malignant adenoma; mesothelioma; perithelioma; suprarenal epithelioma. Some authors appear to give the name carcinoma to all cortical tumors.

DEFINITION. This differs from the adenoma in that it is invasive and metastasizes.

ORIGIN. The question will remain as to whether the carcinoma originates as such or is a change from an adenoma.

CLINICAL FEATURES. The highest incidence is in two periods: the first is from childhood to young adult life, and the second is in middle life. Females are affected more often than males, the preponderance being greater in early life. About 40 percent of cortical tumors in early life are carcinomas, but the proportion of carcinomas is greater in adult life. Of the 12 cases of feminizing cortical tumors reported, 9 died with metastases. Only one of the 12 occurred before puberty and this was benign.

In adults, attention is attracted to the tumor by its size, by metastasis, and sometimes by pain. In early life this may also be true, but generally the first indications are hormonal and metabolic alterations like those described above for adenoma.

DESCRIPTION. Carcinoma is more often bilateral than is adenoma, and the size is generally larger. One tumor of seven kilograms is reported in a boy 6 years old. Weights of 1,000 grams are not rare. The smaller tumors may be completely encapsulated, and the only gross evidence of malignant disease is metastasis. However, parts of the capsule may be thinned because of invasion. Even the large tumors are partly encapsulated. The color is like that of the adenoma but the tumor is softer, more friable, and more subject to necrosis and hemorrhage (plate III). Direct invasion of surrounding structures is not extensive, but the tumor may grow into the adrenal vein. From the right vein it may extend into the vena cava and from the left into the renal vein and

Plate III. Drawing of cortical carcinoma of adrenal. Same case as figure 10. Tumor is only partly encapsulated, and is adherent to but does not invade kidney. Size of tumor indicated by size of kidney. A. F. I. P. Neg. Acc. No. 218755–C7.

the vena cava. Metastasis by blood stream is first into the lungs and by lymphatics into the para-aortic lymph nodes and thence into the mediastinum and elsewhere. The metastases correspond in appearance to the primary tumor.

MICROSCOPIC. There may be no greater pleomorphism, vascularity, or mitotic activity than in the adenoma. However, those features may be pronounced and with masses of spindle-shaped cells containing little or no lipid; such pictures, however, may also be found in adenoma (figs. 17, 19, 21). Mitotic figures may be numerous and of abnormal configuration. Hemorrhage and necrosis may be extensive. The criterion, microscopically, is invasion into or through the capsule.

TREATMENT. If metastases be evident, no special treatment is available. The tumor does not respond to irradiation. Otherwise, surgical excision is practiced as for the adenoma. Symptoms may be relieved for a few months but recurrences and metastases, or both, frequently ensue.

References

Albright, Fuller. Cushing's syndrome. Its pathological physiology, its relationship to the adrenogenital syndrome, and its connection with the problem of the reaction of the body to injurious agents ("alarm reaction" of Selye). The Harvey Lectures, 38: 123–186, 1942–43.

Armstrong, C. N., and Simpson, J. Adrenal feminism due to carcinoma of the adrenal cortex. A case report and review of the literature. Brit. M. J., 1: 782–784, 1948.

Broster, L. R., and Patterson, J. An unusual case of adrenal carcinoma with a note on the application of a new colour test. Brit. M. J., 1: 781–782, 1948.

Broster, L. R., and Vines, H. W. C. The Adrenal Cortex. A Surgical and Pathological Study. London: H. K. Lewis & Co., Ltd., 1933.

Cahill, G. F., Melicow, M. M., and Darby, H. H. Adrenal cortical tumors. The types of nonhormonal and hormonal tumors. Surg., Gynec., & Obst., 74: 281–305, 1942.

Conn, J. W. Electrolyte composition of sweat. Arch. Int. Med., 83: 416–428, 1949.

Geschickter, C. F. Suprarenal tumors. Am. J. Cancer, 23: 104–124, 1935.

Goldzieher, M. A. The Adrenal Glands in Health and Disease. Philadelphia: F. A. Davis Co., 1946.

Goormaghtigh, N. The cytology of functioning adrenal cortex tumors. Am. J. Cancer, 38: 32–40, 1940.

Hain, A. M. Adrenal tumours and pseudo-hermaphroditism: a hormone study of cases. J. Path. & Bact., 59: 267–292, 1947.

Hartman, F. A., and Brownell, K. A. The Adrenal Gland. Philadelphia: Lea & Febiger, 1949.

Hirschmann, H. Steroid excretion in a case of adrenocortical carcinoma. I. Isolation of a Δ^5-androstenetriol-3(β), 16, 17. J. Biol. Chem., 150: 363–379, 1943.

Hirschmann, H., and Hirschmann, F. B. Steroid excretion in a case of adrenocortical carcinoma. II. An examination of the nonketonic fraction precipitable with digitonin. J. Biol. Chem., 157: 601–612, 1945.

Hirschmann, H., and Hirschmann, F. B. Steroid excretion in a case of adrenocortical carcinoma. III. The isolation of Δ^5-pregnanediol-3(β), 17(β)-one-20 and of 17a-methyl-Δ^5-d-homoandrostenediol-3(β), 17a(α)-one-17. J. Biol. Chem., 167: 7–25, 1947.

Josephson, B. The adrenal cortical syndrome in a case with tumor from an accessory adrenal gland. Acta med. Scandinav., 90: 385–396, 1936.

Kepler, E. J., and Keating, F. R. Diseases of the adrenal glands. II. Tumors of the adrenal cortex, diseases of the adrenal medulla and allied disturbances. Arch. Int. Med., 68: 1010–1036, 1941.

Kolodny, A. Suprarenal virilism in a woman. (Tumor of extrarenal suprarenal rest.) J. A. M. A., 102: 925–926, 1934.

Levin, Louis. On the possible relationship between the adrenocortical function and the leukemic state. Cancer, 1: 413–418, 1948.

Soffer, L. J. Diseases of the Adrenals. 2d ed. Philadelphia: Lea & Febiger, 1948.

Uotila, U. U. On the fuchsinophile and pale cells in the adrenal cortex tissue of the fowl. Anat. Record, 75: 439–449, 1939.

Vulpian, A. Note sur quelques reactions propres à la substance des capsules surrénales. Compt. rend. Acad. d. sc., Paris, 43: 663–665, sem. 2, 1856.

Weber, E. J., and Menten, M. L. Histologic studies on a virilizing tumor of the adrenal cortex. Am. J. Path., 24: 293–303, 1948.

Wilkins, L. A feminizing adrenal tumor causing gynecomastia in a boy of 5 years contrasted with a virilizing tumor in a 5-year-old girl. J. Clin. Endocrinol., 8: 111–132, 1948.

Wu, S. D. Carcinoma of the adrenal cortex. Chinese M. J., Suppl., 3: 52–93, 1940.

Figure 10. Boy 3½ years old and 103 cm. tall. Note macrogenitosomia precox. Abdomen enlarged because of size of tumor. Erections but no emissions. Large tumor with invasion of capsule. Dead from metastases 6 months after operation. See figures 14, 17, 19, and plate III. (Patient of Dr. James Joelson.) A. F. I. P. Neg. Acc. No. 218755–8.

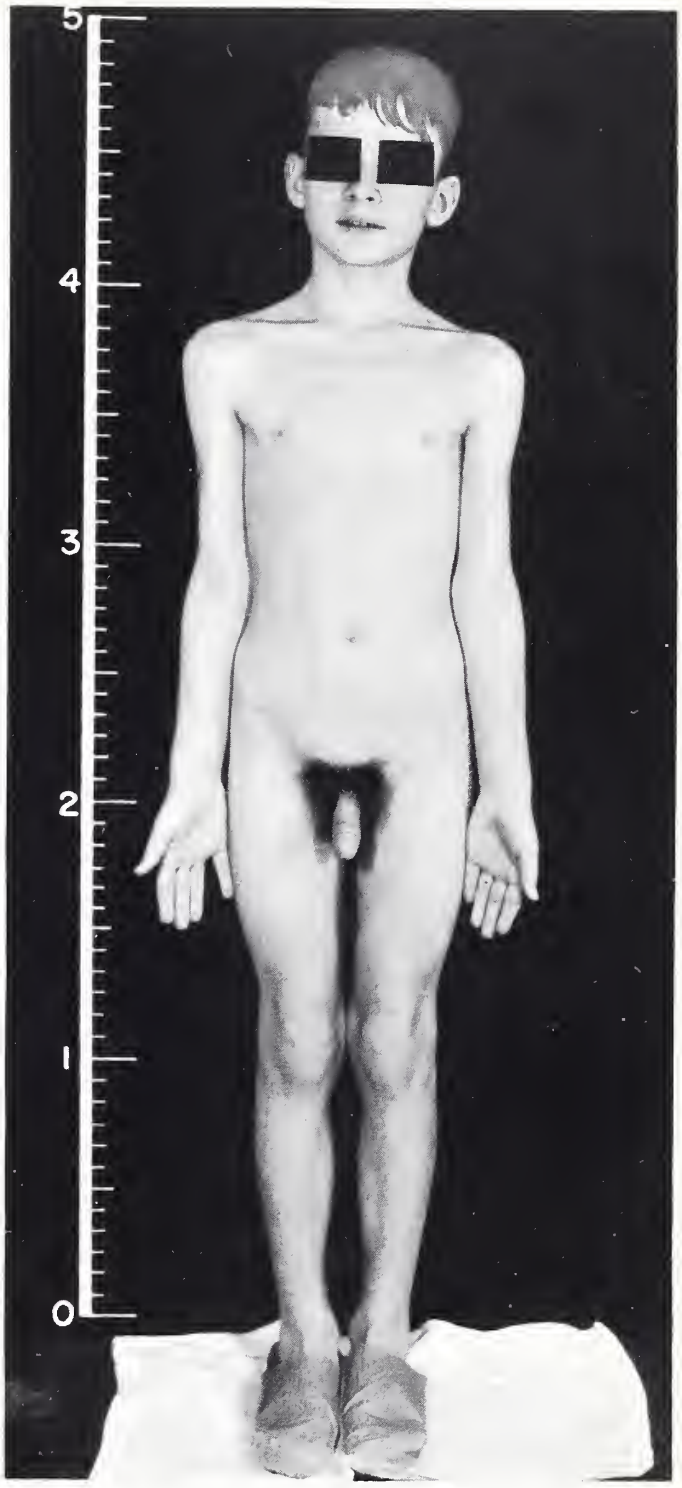

Figure 11. Boy 7 years old. Note macrogenitosomia precox, increased height and pubic hair. Erections but no emissions. Benign cortical adenoma of right adrenal. (Patient of Dr. James Lynch.) A. F. I. P. Neg. Acc. No. 218755–9.

Figure 12. Twins 7 years old. Boy at right with muscular wasting, increased height, large abdomen, and macrogenitosomia praecox. Tumor of left adrenal weighed 1,000 grams and liver with metastases 5,000 grams. The twin brother is apparently a homologous twin and is living and well 8 years after death of brother. (Patient of Dr. F. H. Harvie.) A. F. I. P. Neg. Acc. No. 218755–10.

Figure 13. Boy on left aged 10 years and 10 months with precocious sexual and skeletal development and including increased facial and pubic hair, due to an adrenal tumor; his intelligence was that of 11 years. His normal brother aged 13 years on right. (From A. M. Hain, "Adrenal Tumours and Pseudo-Hermaphroditism: A Hormone Study of Cases", J. Path. & Bact., 59: 280, 1947.) A. F. I. P. Neg. Acc. No. 218755–11.

Figures 12 and 13 portray muscular wasting and hypertrophy, presumably due in part to the influence of the "S" and "N" hormones.

Fig. 12

Fig. 13

Figure 14. Retrograde pyelogram to demonstrate downward displacement of left kidney. Lateral exposures disclosed backward displacement of upper pole. Tumor large and carcinomatous. See figure 10. A. F. I. P. Neg. Acc. No. 218755–12.

Figure 15. Injection of oxygen to demonstrate size and position of benign adenoma of right adrenal. See figure 8. A. F. I. P. Neg. Acc. No. 218755–13.

Fig. 14

Fig. 15

Figure 16. Photomicrograph of cortical adenoma, with vesicular cells arranged like zona glomerulosa. Rich in capillaries and with a large vascular space. × 200. From patient shown in figure 8. A. F. I. P. Neg. Acc. No. 218755–14.

Figure 17. Photomicrograph of cortical carcinoma. Cells poor in lipid but with nestlike arrangement and vascularity as in figure 16. No greater pleomorphism than in figure 16, yet the tumor was malignant. See figure 10. ×200. A. F. I. P. Neg. Acc. No. 218755–15.

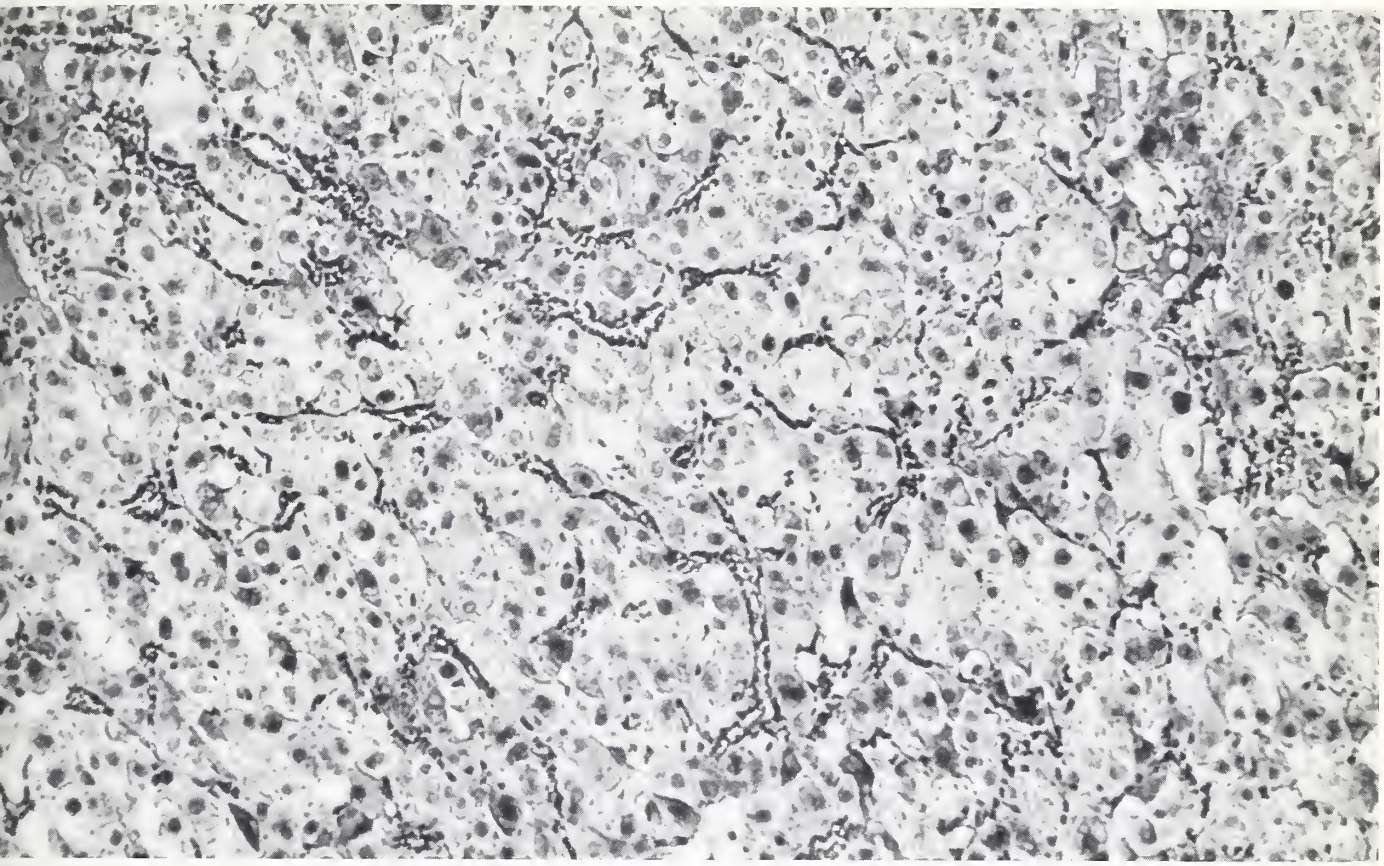

Fig 16

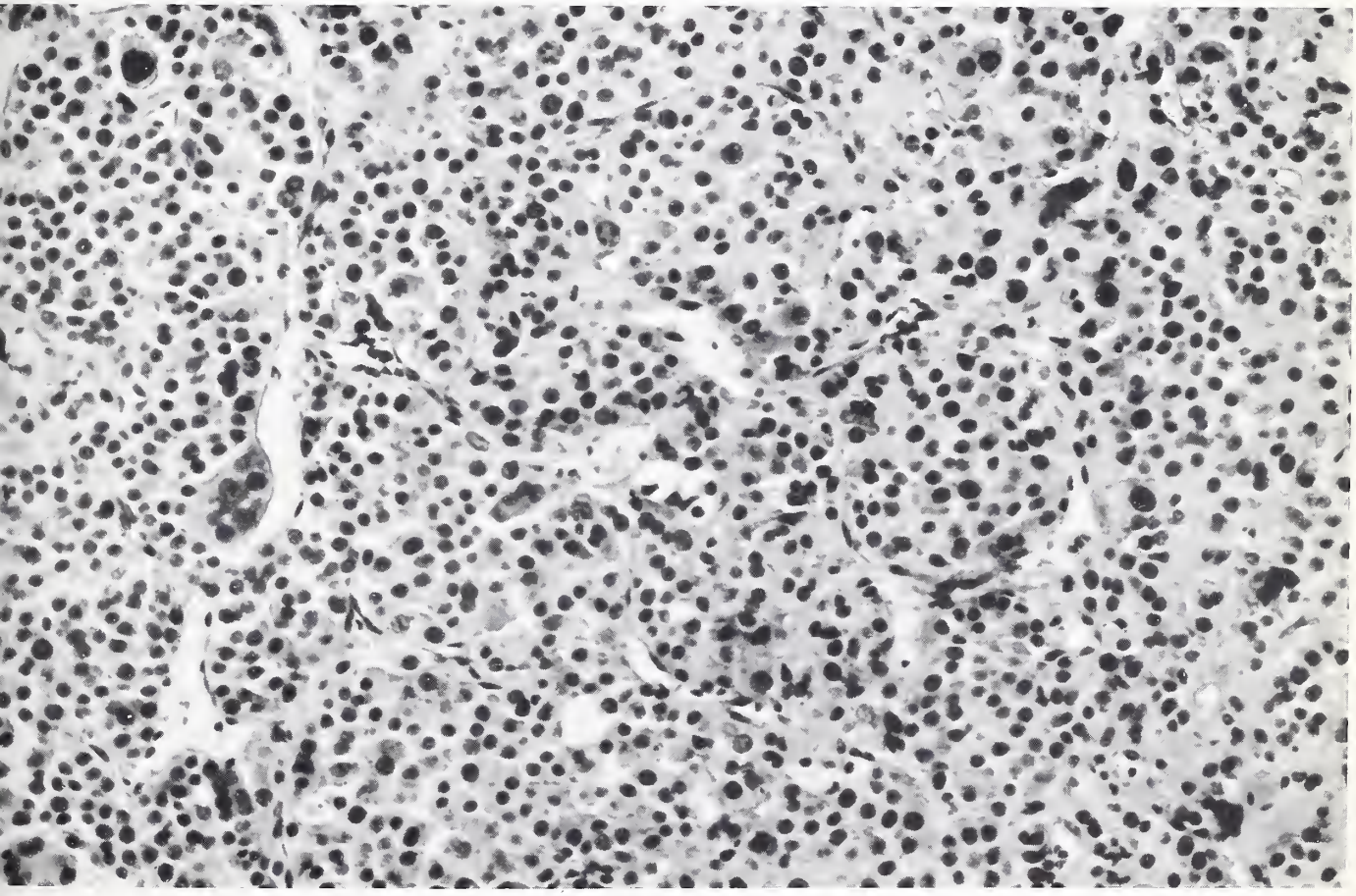

Fig. 17

Figure 18. Photomicrograph of periphery of cortical adenoma with cellular arrangement like zona fasciculata. No invasion of capsule. This demonstrates that cortical adenoma does not duplicate cellular arrangement of adrenal cortex. × 200. Same case as figure 8. A. F. I. P. Neg. Acc. No. 218755–16.

Figure 19. Photomicrograph of cortical carcinoma. Considerable pleomorphism of cells and multinucleated cells. Rich vascularity. Similar pleomorphism may occur in benign adenomas. ×225. Same case as figure 10. A. F. I. P. Neg. Acc. No. 218755–17.

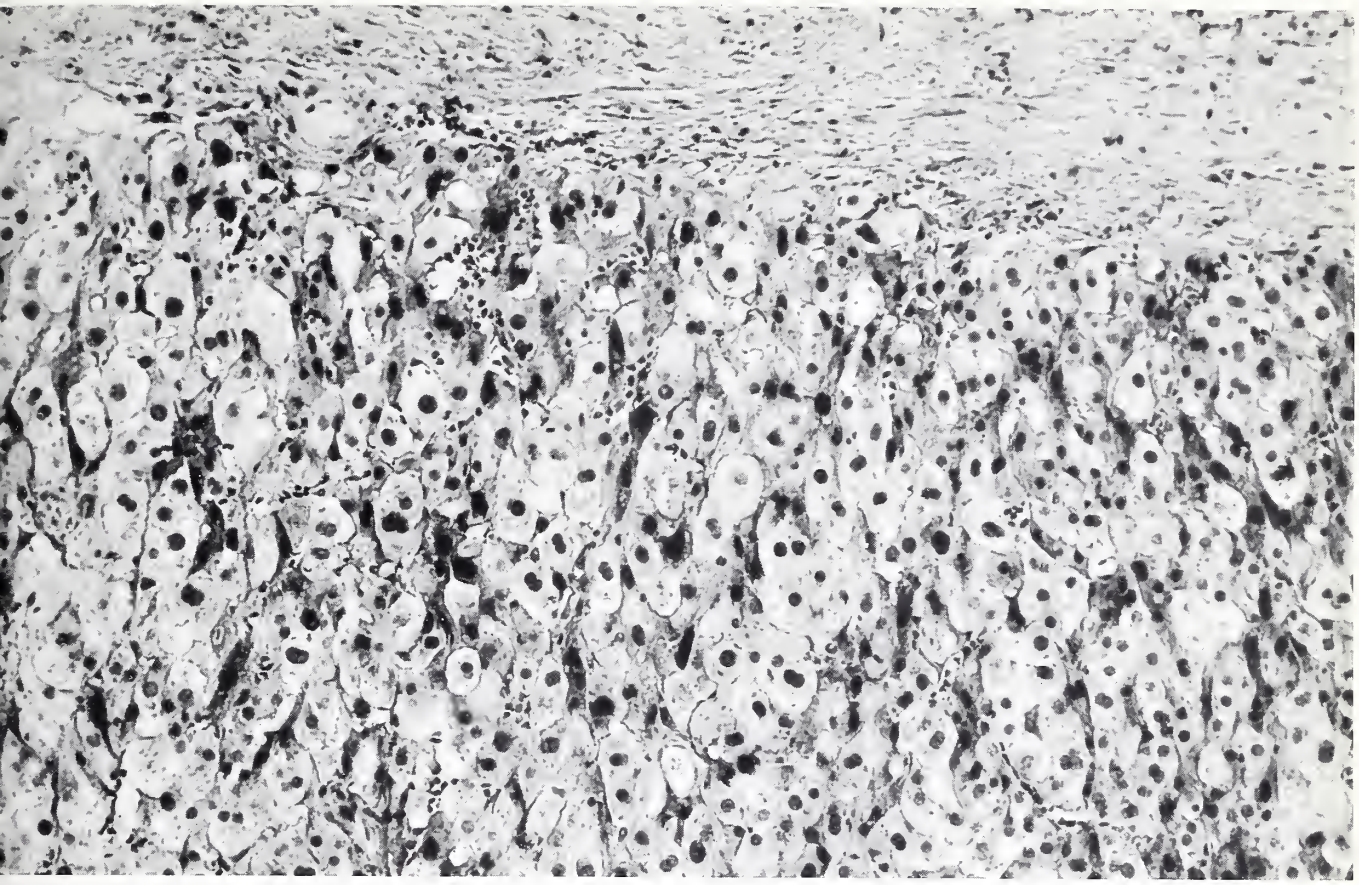

Fig. 18

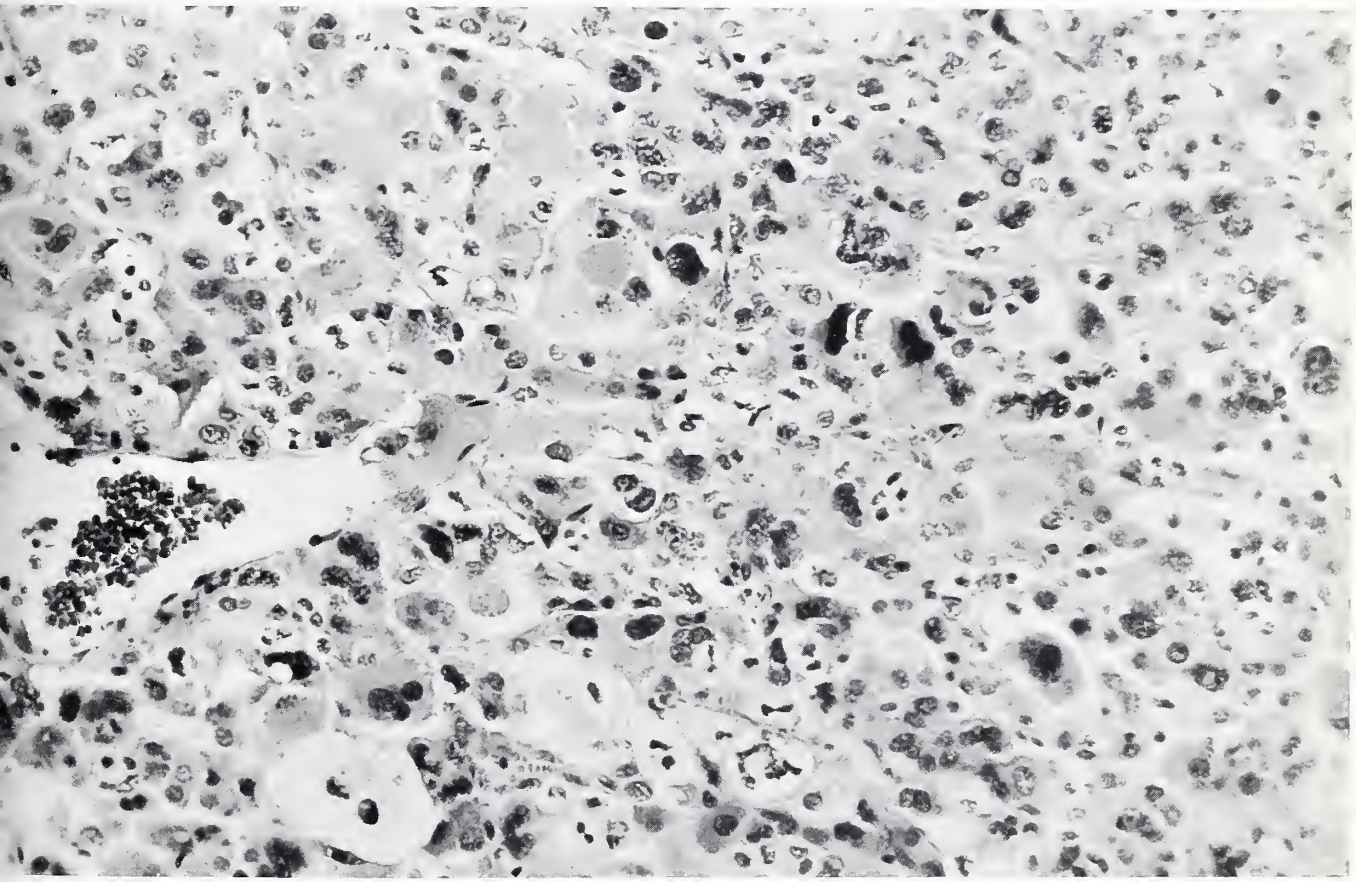

Fig. 19

Figure 20. Photomicrograph of a part of a benign cortical adenoma in a man of 40. Elongated and spindle-form cells without vesicular cytoplasm, similar to some of the cells of pheochromocytoma. × 446. A. F. I. P. Neg. Acc. No. 218755–18.

Figure 21. Photomicrograph of carcinoma of adrenal. In addition to pleomorphism of cells, there is invasion into capsule. White female, 60 years old. × 300. A. F. I. P. Neg. Acc. No. 218755–19.

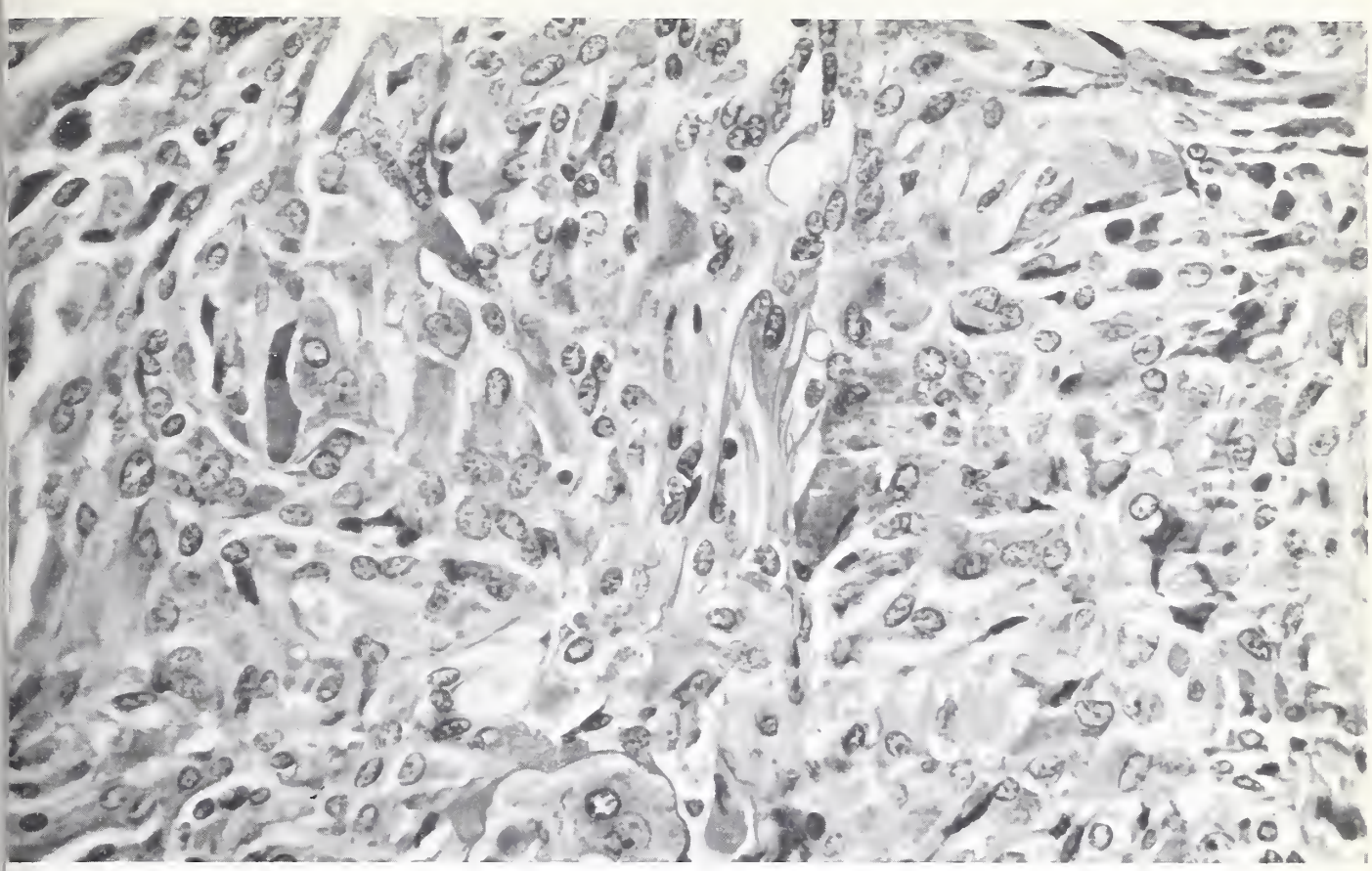

Fig. 20

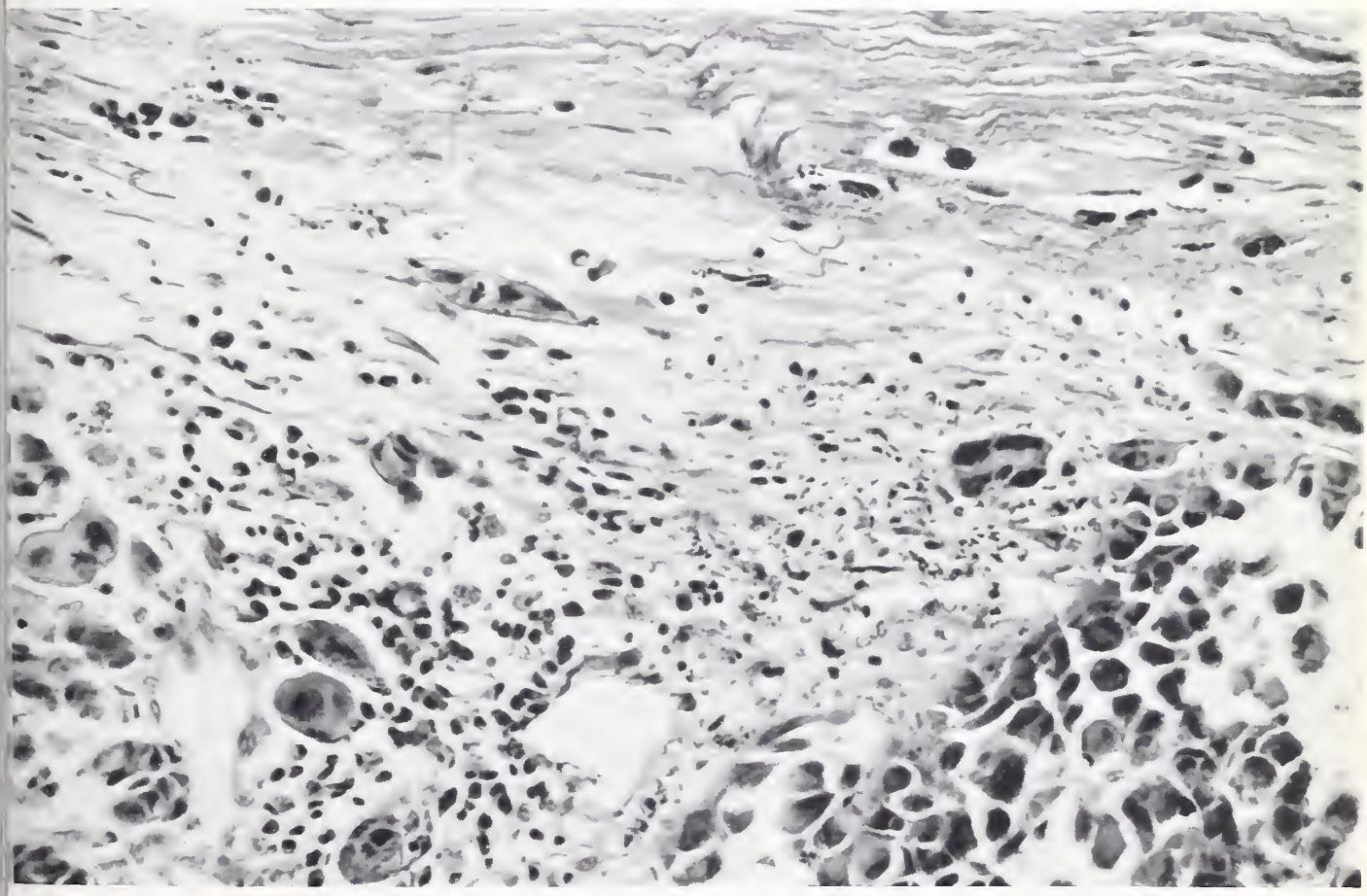

Fig. 21

CORTICAL TUMORS

PROFESSIONAL NOTES AND FINDINGS

TUMORS OF THE MEDULLA

Introduction In the embryo, certain cells of the neural crest migrate ventrally, form the sympathetic ganglia, and give origin to the essential cells of the adrenal medulla. These mature cells are characterized by an affinity for chrome salts and produce epinephrine. They occur in the adrenal medulla and in the paraganglionic chromaffin bodies or paraganglia (Patten). The primitive cell of these sites is the sympathogonia. It differentiates along two lines as indicated in figure 22 which is modified from the original of Bielschowsky. The sympathogonia has a dense nucleus rich in chromatin and a scanty rim of cytoplasm. The sympathoblast is larger, has a less dense nucleus, more cytoplasm, and often a short cytoplasmic process. It differentiates to form the characteristic ganglion cell. Along the other line, the sympathogonia gives rise to the chromaffinic pheochromoblast and the larger pheochromocyte or so-called chromaffin cell. The latter is specifically identified only by its affinity for chrome salts. The nucleus is somewhat vesicular and the cytoplasm slightly granular. Cytoplasmic processes are not found.

Tumors of the adrenal medulla are classified according to the preponderant cell type. These include sympathicogonioma, sympathicoblastoma, ganglioneuroma, and pheochromocytoma. The sympathicogonioma and sympathicoblastoma are often grouped together as neuroblastoma. This term also covers those tumors in which there are mixtures of all three types of cells. Pheochromocytoma and pheochromoblastoma cannot always be classified separately because the tumor usually includes both types of cells.

The following discussion of tumors of the medulla is divided into two parts: (1) tumors of the sympathetic type, and (2) pheochromocytomas.

Sympathicogonioma. Synonyms and Related Terms: Sympathicogonioma (Lat.); sympathicocytoma; sympathicogonioma purum (if with few or no fibrils); sympathicogonioma tenuifibrillare (if with many fibrils); sympathogonioma; sympathogonionoma. Other terms, listed under sympathicoblastoma, have also been applied to sympathicogonioma.

DEFINITION. This is a malignant tumor of the sympathetic nervous system, composed of primitive cells. The characteristic cells resemble the sympathogonia, hence the name sympathicogonioma.

CLINICAL FEATURES. It occurs almost always in or near the adrenal. In various collections of autopsy statistics, the highest figure of incidence is 0.37 percent, but according to Blacklock, it is the most frequent tumor of the sympathetic system in childhood. It is found almost entirely in young chil-

dren, and about 80 percent of cases are observed in the first 2½ years of life. Of 40 cases reported by Lewis and Geschickter, only 5 patients were more than 15 years old, including one in a man of 45 years of age. However, it is probable that tumors in these latter groups would now be classified as sympathicoblastoma. Rarely, the tumor begins in uterine life, and, because of the size of metastases, may cause dystocia. It is somewhat more frequent in females than in males. Familial occurrence has been noted only once, as reported by Dodge and Benner in two siblings.

Usually, attention is first directed to the tumor because of metastases to the liver or the skeletal system. The principal features include enlargement of the abdomen, metastatic lesions, ophthalmic signs, and anemia. Symptoms vary from case to case. Enlargement of the abdomen is chiefly due to metastases, especially in the liver, but sometimes to the original tumor and less often is caused by accompanying ascites. Metastasis to the skull is exhibited by growth outward under the scalp (figs. 23, 24) and sometimes into the cranial cavity (fig. 25); huge masses may be formed. Metastases to long bones may lead to pain, local enlargement, destruction of cortex, and pathological fracture.

Exophthalmos may result from tumor in the orbit, or may be independent of it. Ecchymosis of eyelids is reported in 24 percent of the cases. It may be an early symptom or there may be only edema of the lid. There is a disposition to ischemic necrosis of the pinna of the ears (fig. 23). Moderate anemia, leukocytosis, and fever are frequent. If bone marrow is extensively destroyed, myelophthisic anemia may be profound. This is referred to as the Esser-Herwig type of the disease (Geschickter). Patients with sympathicogonioma usually survive only a few months after discovery of the condition.

A presumptive distinction is made between the Pepper and Hutchison types of the disease. The Pepper type is supposed to include tumors of the right adrenal with metastases principally to the liver. The Hutchison type is thought to include tumors of the left adrenal with skeletal metastases principally to the skull. Analysis of cases has shown that "the position of the metastases is not determined by the site of the original tumor" and that "neither clinically nor anatomically are these eponymic designations justified" (Karsner).

Clinical diagnosis is usually made readily. Adequate biopsy is ordinarily diagnostic. However, if it is from bone, a distinction between metastasis of sympathicogonioma and endothelial myeloma of Ewing and even osteogenic sarcoma is difficult. If fibrils and rosettes are present, there is little danger of confusion. Pyelograms often disclose displacement of the kidney and sometimes a soft tissue shadow. There may be a "moth-eaten" appearance of bones, especially long bones, sometimes with wedge-shaped defects. Diastasis of sutures of the skull, especially the coronal and sagittal ones, may occur. In the metastases projecting from the outer table of the skull, there is often a fine bony trabeculation with the spicules arranged vertically (fig. 24).

Other features of the case help to distinguish this from a similar appearance in meningioma, osteogenic sarcoma, sicklemia, and hereditary leptocytosis (thalassemia).

GROSS. The tumor is usually unilateral but may be bilateral. Whether the latter represents two tumors or metastasis from one is not certain. The size varies from a diameter of a few millimeters to a mass which occupies a large part of the abdominal cavity. The smaller tumors may be encapsulated even when metastasis is observed. The larger tumors may have a partial capsule or none. The color varies. The tumor is soft, and cuts readily. In the cross section, a certain amount of lobulation is evident, the sectioned surface bulges, bleeds freely, and is friable. Although the basic color is white, there is mottling with red hemorrhage, brown blood pigment, and yellow necrosis. The tumor rarely occurs in retroperitoneal tissues except near the adrenal (Drake and Hellwig). Direct extension to neighboring soft tissues may produce great masses of tumor (fig. 26). Metastases may be widespread. Metastatic nodules have much the same appearance as the original tumor.

MICROSCOPIC. Fibrous trabeculae may produce a suggestion of alveolation, but otherwise stroma is scanty. Capillaries are numerous, sometimes as large vascular spaces. There are small arteries and veins (fig. 27). The characteristic cell is about the size of the small lymphocyte or smaller, with a diameter of approximately 7 or 8 microns. The cytoplasm is scanty, clear, and stains poorly. In favorable preparations, rarely a short cytoplasmic process may be seen. The nucleus is usually spherical but may be pyriform. It has a well-defined membrane and is so rich in chromatin that it appears solid. Multinucleated cells may be numerous, but mitotic figures are infrequent. Delicate fibrils vary in number from case to case and in different parts of the same tumor. They are presumably neurofibrils, but silver impregnation is not constant. Drake and Hellwig assert that impregnation is more readily accomplished in the more mature sympathicoblastoma than in the sympathicogonioma. Many of the fibrils are scattered in groups and bundles irregularly through the tumor; however, they may be arranged in clusters of interlacing fibrils, surrounded by the tumor cells resembling the packets of embryonal sympathetic nervous tissue as described by Wright (figs. 28, 29, 30). These are pseudorosettes. Sometimes, however, the surrounding cells may be "polarized" (Wahl) to form real rosettes; yet these do not have the same regularity of form or the radial disposition of fibrils which occurs in the retinal tumor. Foci of hemorrhage and necrosis are frequent.

The term "sympathicogonioma tenuifibrillare" has been applied to the tumors rich in fibrils, and "sympathicogonioma purum" to those with few or no fibrils. However, both forms may be present in the same tumor. In one of our cases the original tumor was rich in fibrils, and the metastases were almost devoid of them. Furthermore, tumors occur in which there are cells

with varying degrees of differentiation up to mature ganglion cells. Cushing and Wolbach report a case in which biopsy disclosed sympathicoblastoma, but ten years later the tumor had become transformed into a ganglioneuroma.

TREATMENT. Recent observations of Sidney Farber, M.D. * The Children's Medical Center, Boston, Mass., indicate that X-irradiation is effective. Six patients with neuroblastoma of the adrenal and multiple metastases in the liver, proved by operation and microscopic examination, are alive and well 3 to 11½ years after diagnosis and beginning of treatment. However, if skeletal metastases were present, the patient has not survived. X-irradiation should be so administered that it does not prevent closure of epiphyses. Martin H. Wittenborg, M.D., Associate Radiologist at the Center, recommends 800 to 1200 R given in 10 to 14 days, usually followed after 3 months by a second course of treatment. If a single tumor cannot be removed completely by operation, there is a 60 percent survival after 3 years, provided no metastases have occurred.

Sympathicoblastoma.* Synonyms and Related Terms: Sympathicoblastoma (Lat.); adrenal sarcoma; gangliosympathicoblastoma; neuroblastoma; neurocytoma; neurosarcoma; round cell sarcoma, (obs.); sympathetic neuroblastoma; sympathigoblastoma; sympathoblastoma; sympathoma; sympathoma embryonale.

Ordinarily, the suffix blastoma indicates a tumor of primitive cell type with a high degree of invasiveness and disposition to metastases. The term sympathicoblastoma is used to indicate a higher degree of differentiation than is true of the sympathicogonioma. Practically, the sympathicoblastoma is less malignant than the sympathicogonioma, especially when it occurs in later periods of life.

GROSS. It is likely to be encapsulated but is otherwise like the sympathicogonioma.

MICROSCOPIC. Sympathoblasts are the principal cellular components; there is only little tendency to the formation of fibrils or pseudorosettes (fig. 34). Metastasis is not frequent or widespread.

Ganglioneuroma. Synonyms and Related Terms: Ganglioneuroma (Lat.); gangliocytoneuroma; ganglioglioneuroma; ganglioma; ganglion cell tumor; ganglioneuroblastoma; ganglioneuroblastoma sympathicum; ganglioneuroma simplex; ganglioneuroma telangiectaticum cysticum; ganglionic neuroma; myelinated nueroma gangliocellulare; neurofibroma ganglionare; neuroganglioma myelinicum verum; neuroma (obs.); neuroma gangliocellulare (Virchow); neuroma gangliocellulare amyelinicum; neuroma gangliocellulare benignum; neuroma verum amyelinicum gangliosum; neuroma verum gangliosum amyelinicum; sympathicocytona (Hortega); unmyelinated neuroma gangliocellulare.

DEFINITION. Ganglioneuroma is a tumor of the sympathetic system, generally not malignant, and is characterized by the presence of mature or immature ganglion cells and neurofibrils.

INCIDENCE. In 1935, McFarland and Sappington collected records of 143 cases. The tumor may occur from infancy to old age and has been reported in the stillborn fetus. Of 102 patients, the age was less than 10 years in 33 cases,

---

* Personal communication from Dr. Farber.

*Sympathicoblastoma and sympathicogonioma are discussed as one unit Fascicle 6, "Tumors of the Peripheral Nervous System."

more than 10 years in 64 cases, and over 60 years in 5 cases. Many are incidental observations at autopsy. The tumor is less frequent in the adrenal than along the paravertebral sympathetic ganglia.

CLINICAL FEATURES. In the adrenal region there may be pain, but almost invariably the tumor is silent. Symptoms vary with the location of the tumor and may simulate the symptoms of other tumors in these sites: for example, Horner's syndrome when the superior pulmonary sulcus is involved, or shortness of breath when the tumor occurs in the mediastinum. The tumor generally does not invade or metastasize; however, metastasis from typical ganglioneuroma has been reported.

DESCRIPTION. The tumor is spherical or ovoid, grayish white, sharply defined from surrounding structures, and has a delicate capsule. In or near the adrenal it is usually small, of the order of 20 to 50 grams, but in other situations it may attain a weight of 200 grams or more. However, Ewing refers to one as large as a man's head. It cuts with moderate resistance. The sectioned surface is pale gray, moist, nonbulging, and somewhat fibrillated.

MICROSCOPIC. The ganglion cells (fig. 31) are characteristic. They are, usually, mature and have distinct nucleoli. There may be variations such as smaller cells, dense nuclei, sometimes multinucleated cells, and in some cells peripheral position of the nuceli. Pigment is absent. Cytoplasmic processes are often identified. The cells are scattered diffusely or arranged in clusters. There are many nonmedullated nerve fibrils and often neurinomatous fibrils with nuclei like those of the cells of Schwann. Mesoblastic stroma and vascularity are scanty.

DIFFERENTIATION. The usual tumor is characteristic. In occasional instances the ganglion cells are immature, but their presence together with neurofibrils and neurinomatous tissue assures the diagnosis. The characteristics of the malignant forms are given below.

TREATMENT. If any is required, it is surgical excision.

Malignant Ganglioneuroma. Synonyms and Related Terms: Ganglioneuroma malignum (Lat.); gangliocytoma; ganglioneuroblastoma; ganglioneurosarcoma; gangliosympthicoblastoma; immature ganglioneuroma; metastasizing ganglioneuroma; neuroma gangliocellulare malignum; partly differentiated ganglioneuroma; sympathetic neuroma; sympathoblastoma. Von Fischer distinguished between (1) ganglioneuroblastoma immaturum in which there are nodules of immature sympathetic cells; and (2) ganglioneuroma imperfectum in which all forms of differentiation are interspersed from sympathogonia to ganglion cells. It is inevitable that terminology will vary for a rare group of tumors with pleomorphic potentialities. Malignant ganglioneuroma is the preferred term for the whole group. This may be subdivided into a nodular type which is also called discrete type, immature ganglioneuroma and ganglioneuroblastoma immaturum, and into a mixed type called a diffuse type and ganglioneuroma imperfectum. (See Fascicle 6, p. 38, "Tumors of the Peripheral Nervous System."

DEFINITION. The malignant ganglioneuroma is morphologically similar to the benign but differs in behavior in that it invades locally and may metastasize.

GROSS. The tumor is like the ganglioneuroma except that the capsule is incomplete or absent. The tumor is often richly vascular and there may be small hemorrhages and small foci of necrosis.

MICROSCOPIC. The components are much the same as in the ganglioneuroma. However, ganglion cells may be immature and multinucleated. There may be numerous more primitive cells, sympathogonia, and sympathoblasts. These may determine the malignant character. Furthermore, other components of the tumor may become malignant (figs. 32, 33*). This is probably more true of the fibromatous than the neurinomatous elements. Even so, the picture is more like an undifferentiated spindle cell sarcoma than a typical malignant Schwannoma (neurogenous sarcoma).

TREATMENT. It is thought that if metastases are not present, complete surgical excision may be effective. There is no proof that irradiation is curative.

References

Blacklock, J. W. S. Neurogenic tumors of the sympathetic system in children. J. Path. & Bact., 39:27–48, 1934.

Bothman, L., and Blankstein, S. S. The eye in adrenal sympathicoblastoma (Neuroblastoma). Importance of ocular findings, with first pathologic report of metastatic tumor in choroid. Arch. Ophth., 27:746–761, 1942.

Cushing, H., and Wolbach, S. B. The transformation of a malignant paravertebral sympathicoblastoma into a benign ganglioneuroma. Am. J. Path., 3:203–216, 1927.

Dodge, H. J., and Benner, M. C. Neuroblastoma of the adrenal medulla in siblings. Rocky Mountain M. J., 42:35–38, 1945.

Drake, R. L., and Hellwig, C. A. Retroperitoneal sympathicoblastoma without involvement of adrenal glands. Arch. Path., 33:922–929, 1942.

Ewing, J. Neoplastic Diseases. A Treatise on Tumors. 4th ed. Philadelphia: W. B. Saunders Co., 1940.

Karsner, H. T. Distribution of metastases of neuroblastoma of the adrenal. Tr. A. Am. Physicians, 57:209–211, 1942.

Lewis, D., and Geschickter, C. F. Tumors of the sympathetic nervous system. Arch. Surg., 28:16–58, 1934.

McFarland, J., and Sappington, S. W. A ganglioneuroma in the neck of a child. Am. J. Path., 11:429–448, 1935.

Patten, B. M. Human Embryology. Philadelphia: The Blakiston Co., 1946.

von Fischer, R. F. Zur Kenntniss der Neurome des Sympathikus. Frankf. Ztschr. f. Path., 28:603–628, 1922.

Wahl, H. R. Neuroblastomata: With a study of a case illustrating the three types that arise from the sympathetic system. J. Med. Research, 25:205–260, 1914.

Wahl, H. R., and Craig, P. E. Multiple tumors of the sympathetic nervous system. Report of a case showing a distinct ganglioneuroma, a neuroblastoma and a cystic calcifying ganglioneuroblastoma. Am. J. Path., 14:797–807, 1938.

Wright, J. H. Neurocytoma or neuroblastoma, a kind of tumor not generally recognized. J. Exper. Med., 12:556–560, 1910.

---

* Dr. A. P. Stout has studied this tumor and believes that the spindle cells shown in this illustration are of Schwannian and not of mesodermal origin.

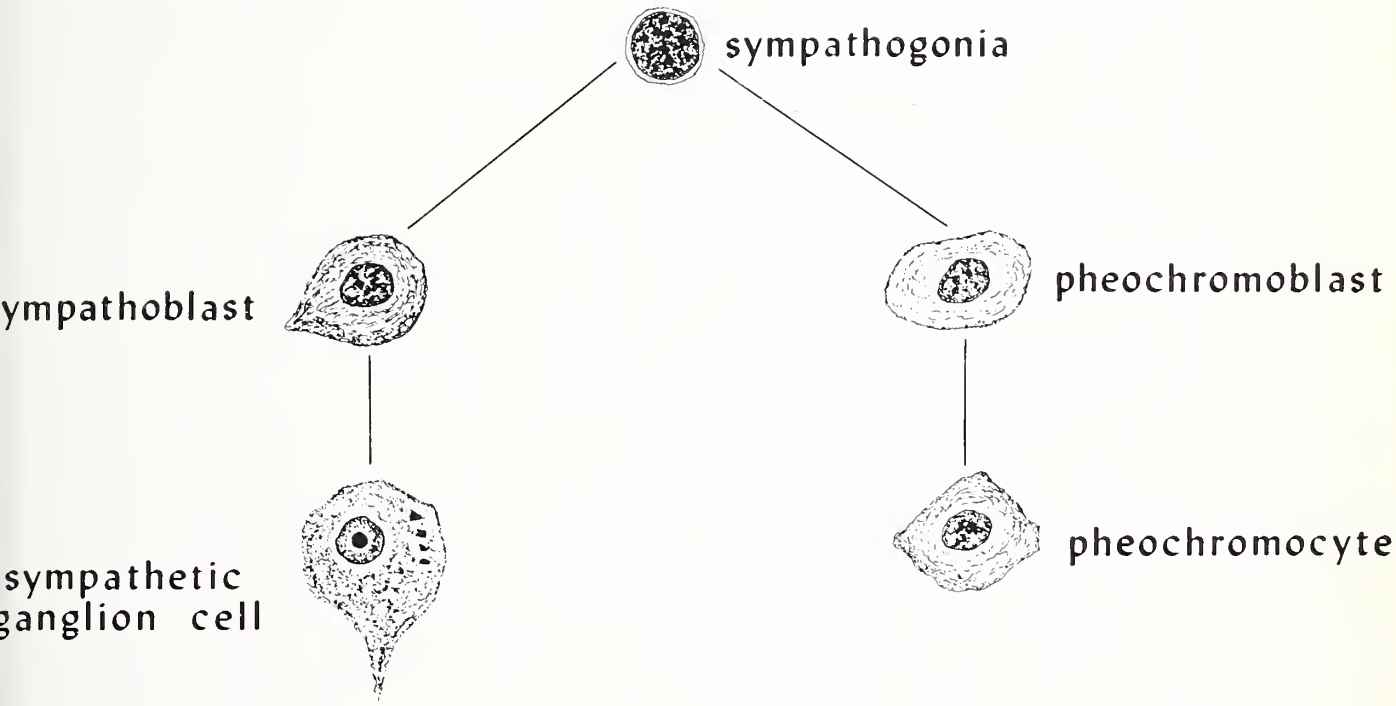

Figure 22. Diagram modified from Bielshowsky to show development of cells of the sympathetic nervous system. The chromaffin cell is the pheochromocyte. Not only has the pheochromocyte the form in the illustration, but it may be elongated and of spindle form. A. F. I. P. Neg. Acc. No. 218755–20.

Figure 23. Profile photograph of a white female 4 years old, with sympathicogonioma. A cranial metastasis protrudes above the anterior hair line. Note edema and ecchymosis of the eyelids and ischemic necrosis of the pinna of the ear. See figures 24, 25, 26, 27, 29, and 30. A. F. I. P. Neg. Acc. No. 218755–21.

Figure 24. Roentgenogram of skull of patient (fig. 23) to show the soft tissue shadow and vertical lines of calcification in the boss under the scalp. The skull plate is eroded. A. F. I. P. Neg. Acc. No. 218755–22.

Fig. 23



Fig. 24

Figure 25. Photograph of base of skull in same patient as figure 23, with metastasis in base of anterior fossa. A. F. I. P. Neg. Acc. No. 218755–24.

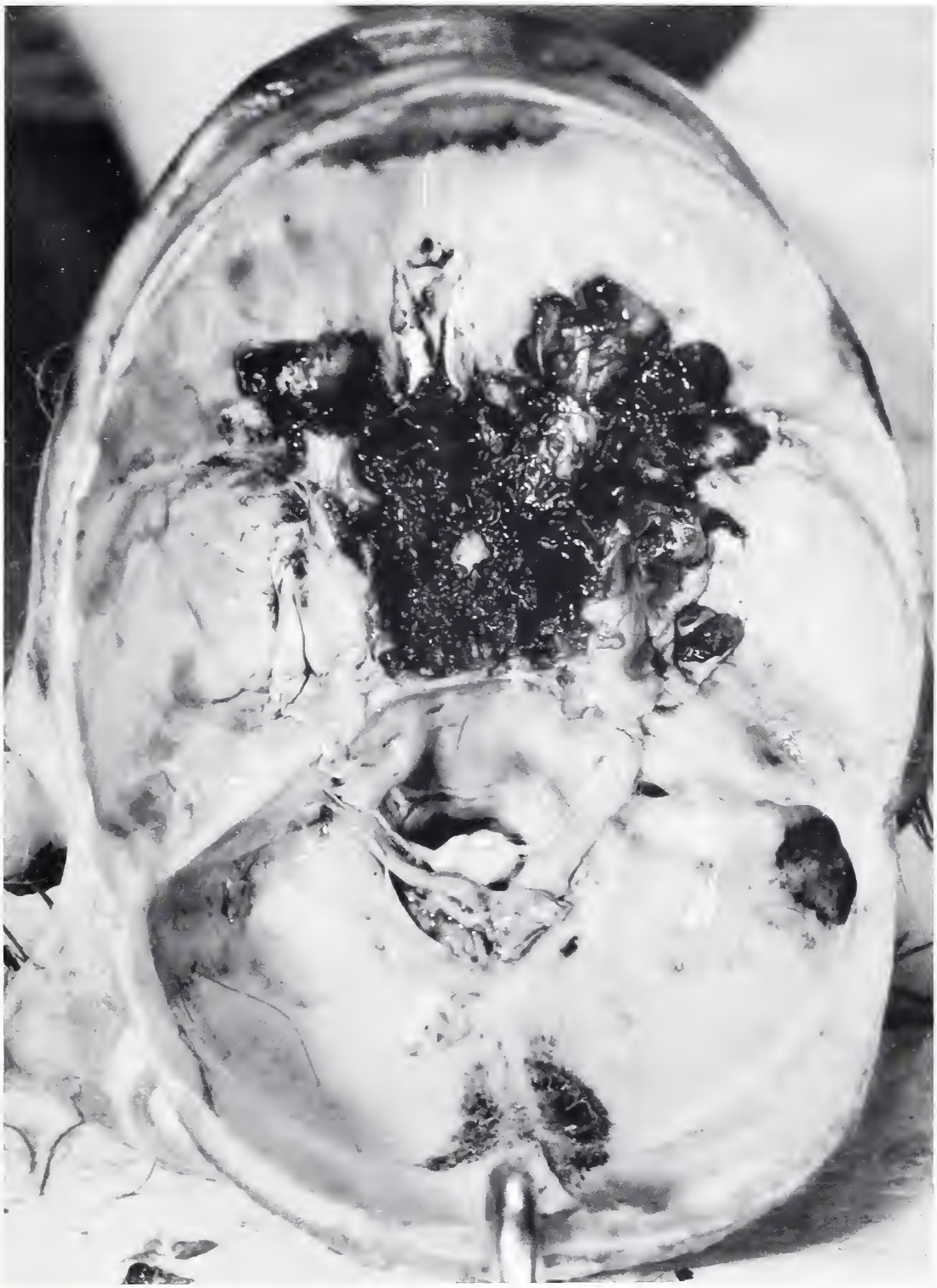

Fig. 25

Figure 26. Photograph of cross section of sympathicogonioma of child pictured in figure 23. It is above and medial to the kidney and extends to the right side of the spine. A. F. I. P. Neg. Acc. No. 218755–23.

Figure 27. Photomicrograph of sympathicogonioma in same case as figure 23. Under the capsule of the adrenal is a rim of cortical tissue, beneath which is the richly vascularized tumor. × 168. A. F. I. P. Neg. Acc. No. 218755– 25.

Fig. 26

Fig. 27

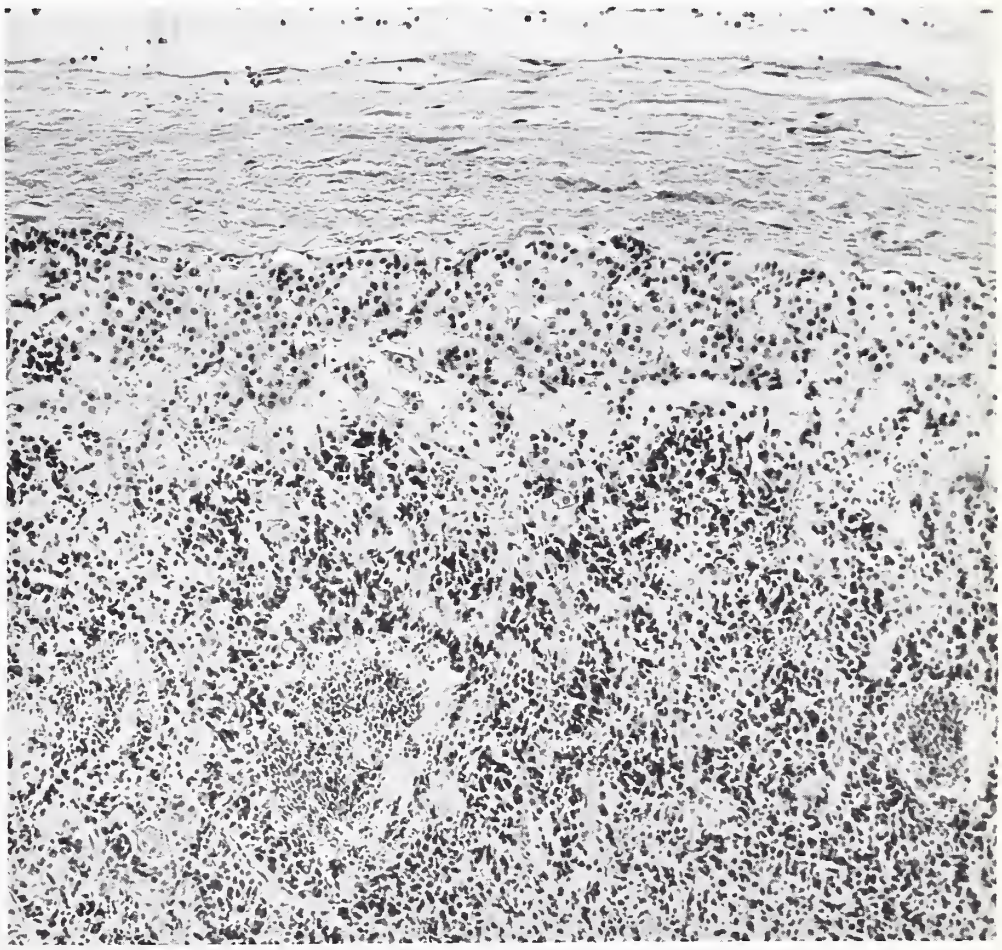

Figure 28. Comparing embryonal sympathetic ganglia and "neuroblastoma." "A" is a primary tumor. "B," "C," "D," and "E" are from the sympathetic ganglia of human embryos. "F" and "G" are foci of metastases in lymph nodes. There is a striking resemblance between the pseudorosettes and bundles of fibrils in the tumors and in the embryonal sympathetic ganglia. This was the first proof of the histogenesis of sympathicogonioma. (From James Homer Wright, "Neurocytoma and Neuroblastoma, A Kind of Tumor not Generally Recognized," J. Exp. Med. 12: 556, 1910.) A. F. I. P. Neg. Acc. No. 218755–43.

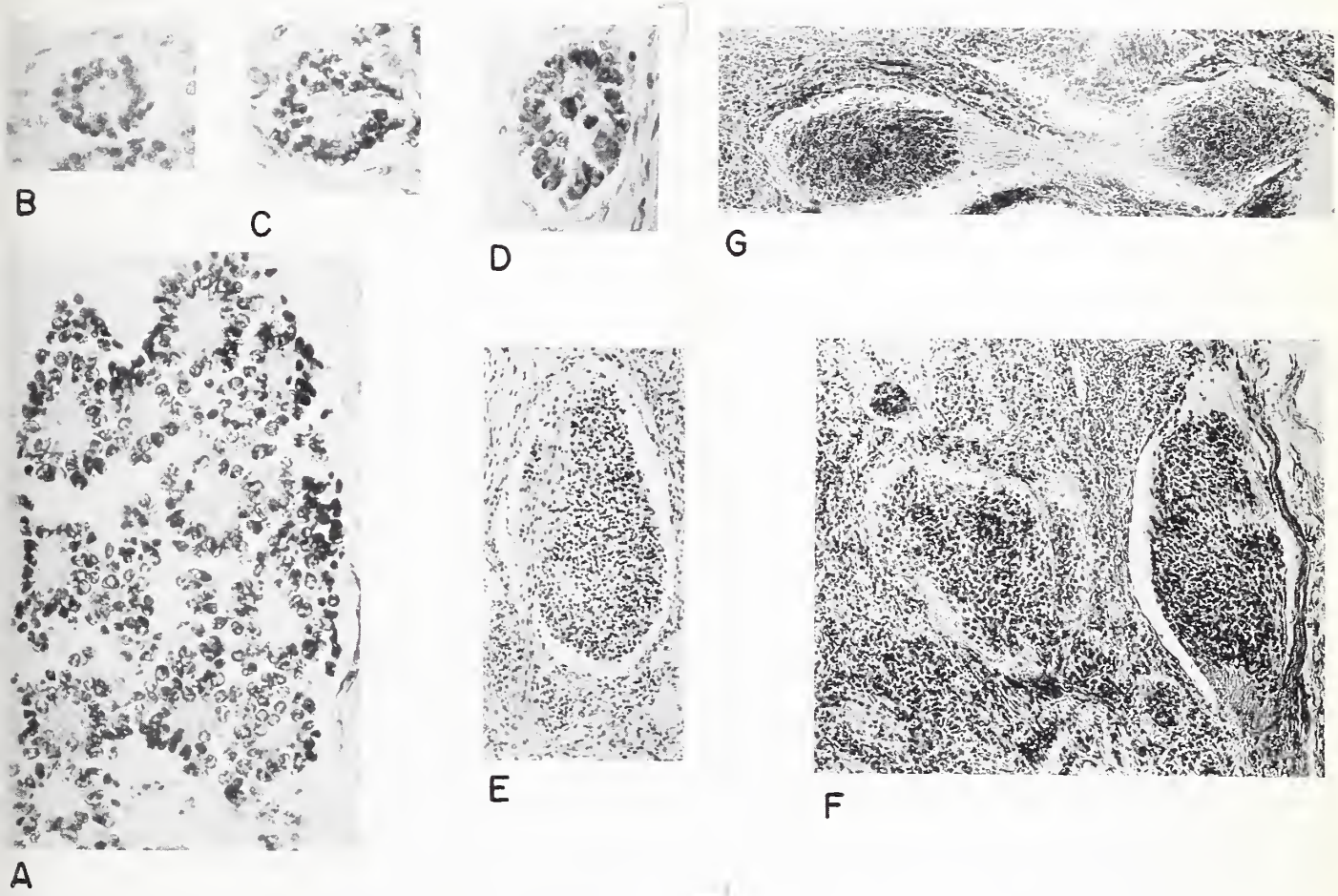

Fig. 28

Figure 29. Photomicrograph of sympathicogonioma in same case as figure 23. Note cell type, rich vascularity, one band of connective tissue, and numerous fibrils, which in places form pseudorosettes. × 475. A. F. I. P. Neg. Acc. No. 218755–26.

Figure 30. Photomicrograph of metastasis of sympathicogonioma in liver. Same case as figure 23. Hepatic lobule replaced but remnants of portal spaces remain. This metastasis is practically devoid of fibrils. × 475. A. F. I. P. Neg. Acc. No. 218755–27.

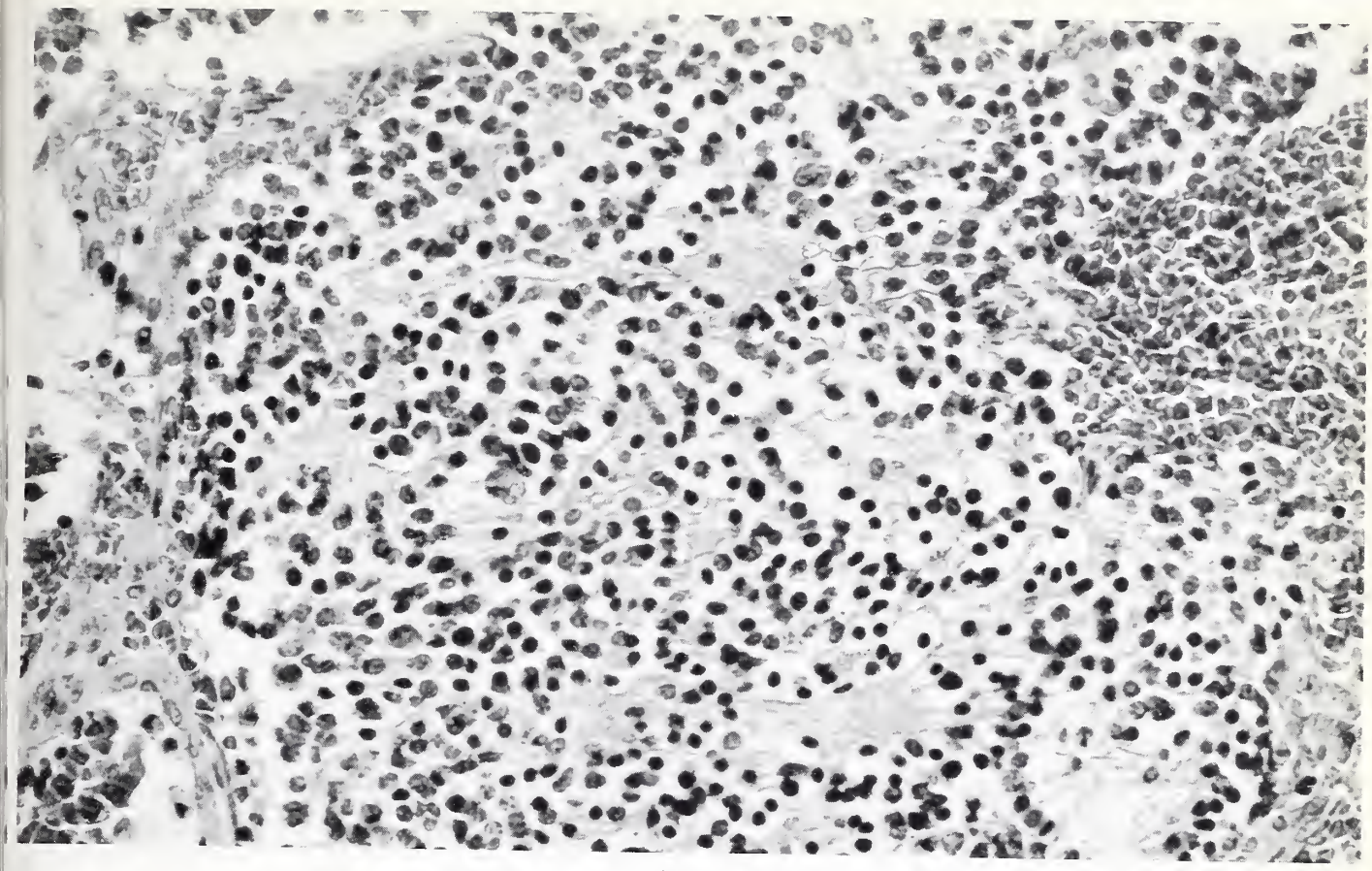

Fig. 29

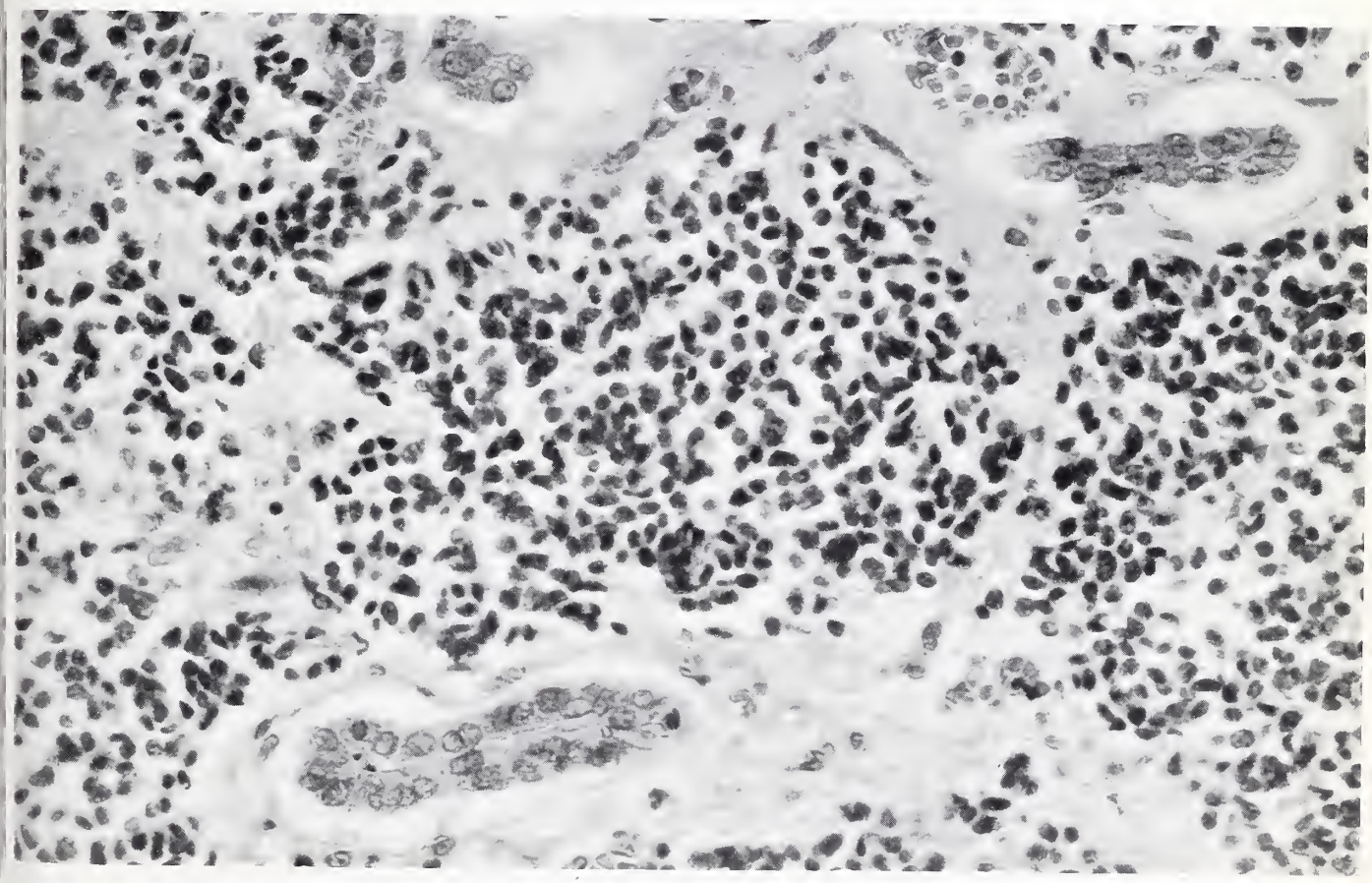

Fig. 30

Figure 31. Photomicrograph of field of ganglioneuroma with mature ganglion cells and spindle-shaped Schwann cells. ×200. A. F. I. P. Neg. Acc. No. 218755–29.

Figure 32. Photomicrograph of an undifferentiated "malignant ganglioneuroma." Ganglion cells in the cluster vary in character, and in the right center is one with numerous cytoplasmic processes. The network in the center is of nonmedullated neurofibrils. To the left are connective tissue and Schwann cells. × 475. (Case of Dr. R. S. Haukohl, Milwaukee.) A. F. I. P. Neg. Acc. No. 218755–30.

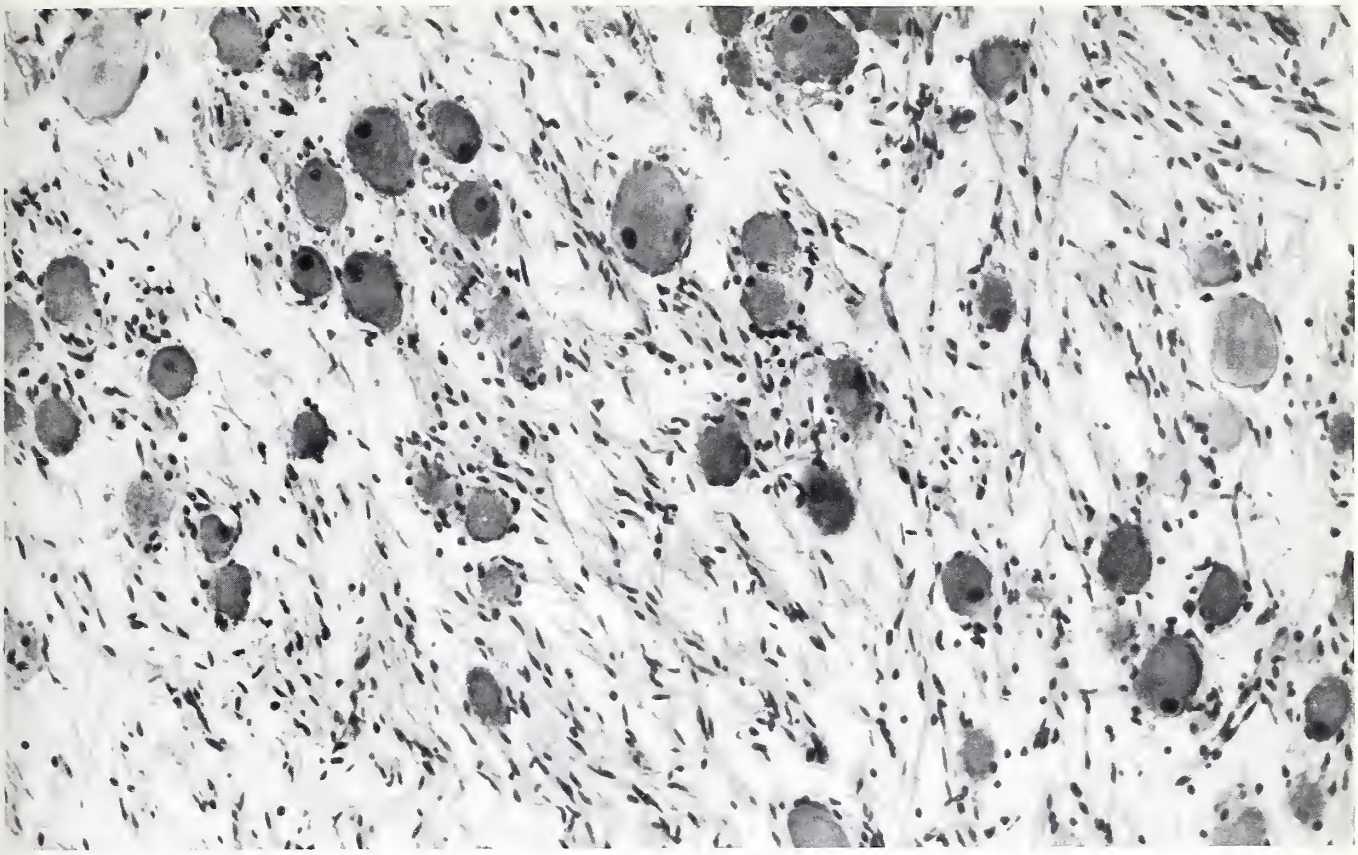

Fig. 31

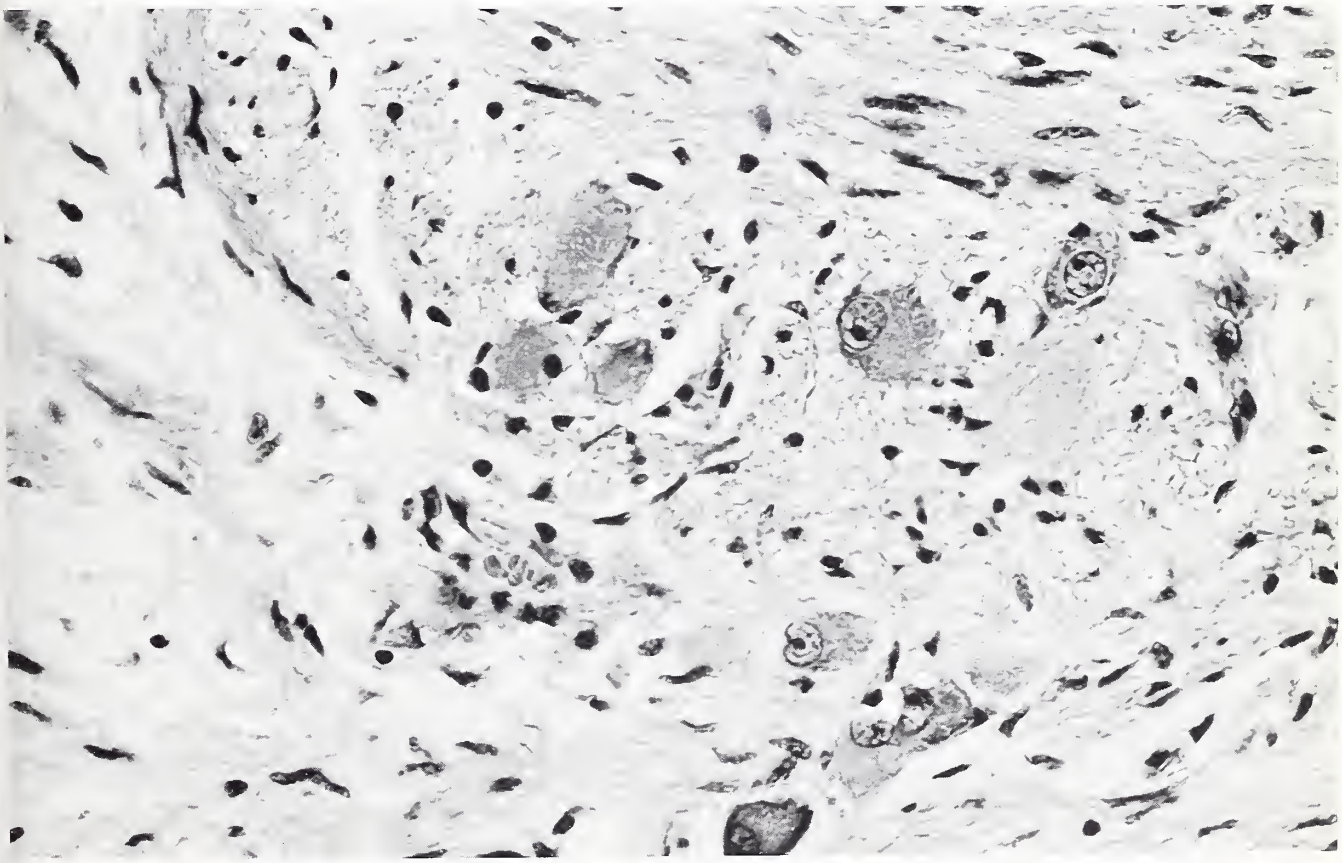

Fig. 32

Figure 33. Photomicrograph of sarcomatous part of the tumor illustrated in figure 32. Immature spindle cells have invaded a vein. The author interprets these as of connective tissue origin (a spindle cell sarcoma), but in the opinion of Dr. A. P. Stout, they are Schwann cells. × 475. A. F. I. P. Neg. Acc. No. 218755–31.

Figure 34. Photomicrograph of sympathicoblastoma in a white male 5 months old. Patient alive and well three years after operation. Size of cells may be compared with those of figures 29 and 30, all at the same magnifications. The tumor is alveolated by delicate interlacing connective tissue bands (see arrows). The cells are larger than those of the sympathicogonioma, with more cytoplasm and with vesicular nuclei. There are a few multinucleated forms. Fibrils are scanty. Inserted is the one pseudorosette found in many sections. × 475. (Patient of Dr. J. E. McClelland.) A. F. I. P. Neg. Acc. No. 218755–28.

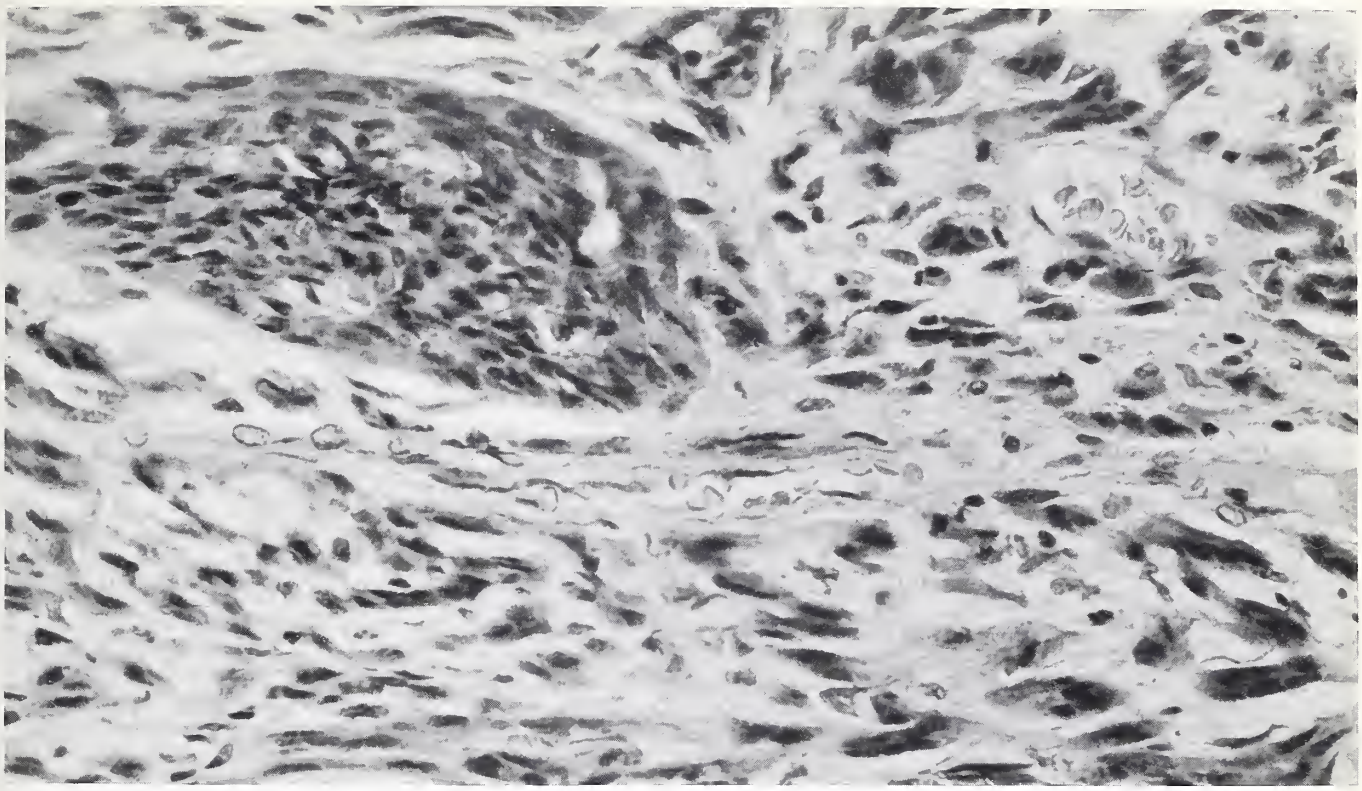

Fig. 33

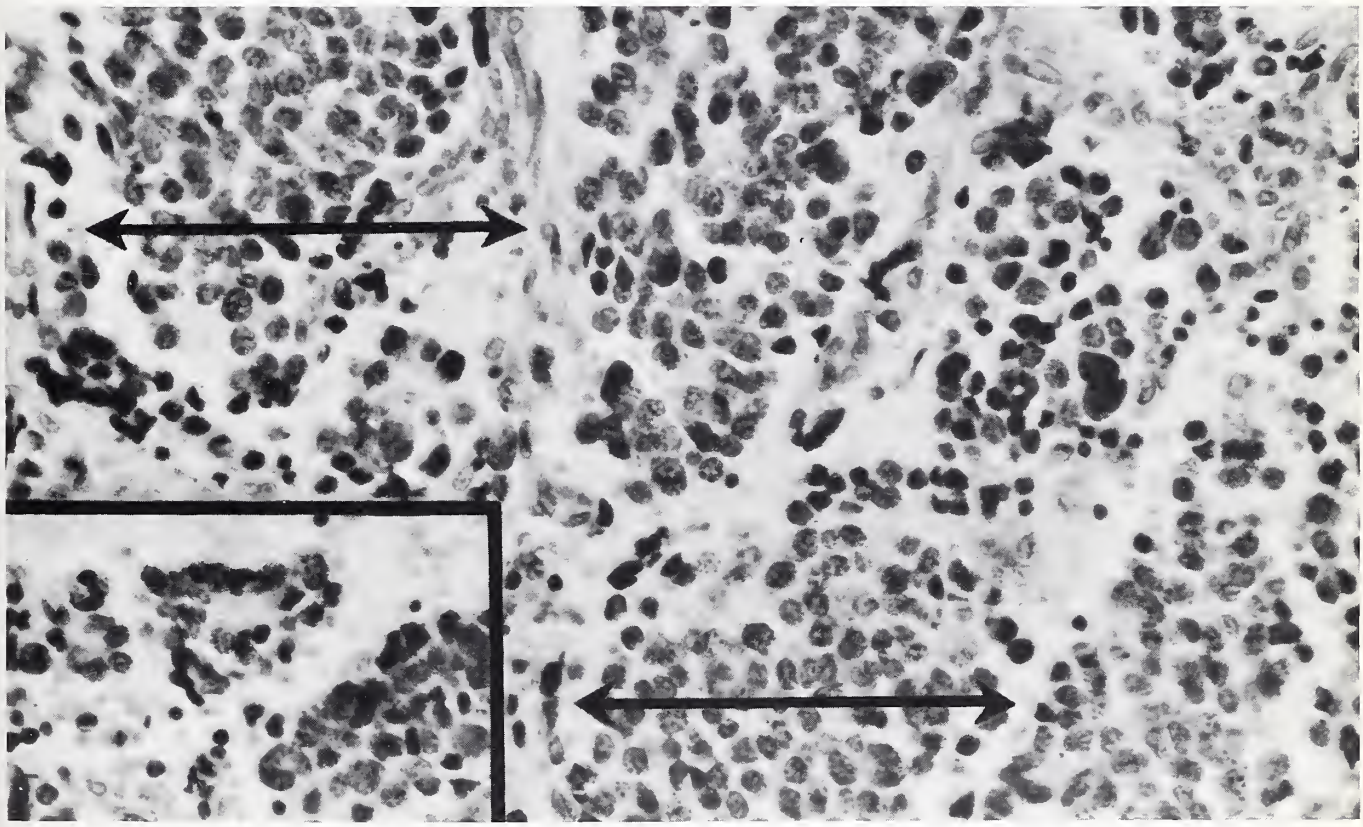

Fig. 34

MEDULLARY TUMORS

PROFESSIONAL NOTES AND FINDINGS

Pheochromocytoma. Synonyms and Related Terms: Phaiochromocytoma (Lat.); chromaffin cell tumor; chromaffinoma; chromophile tumor; cystic medullary struma of adrenal; medullary adenoma of adrenal; paraganglioma. Certain authors use paraganglioma as an inclusive term for all tumors of the parasympathetic system, while others use pheochromocytoma as an inclusive term. Still other pathologists restrict the term paraganglioma to locations outside the adrenal and its immediate neighborhood. Here pheochromocytoma designates functional parasympathetic tumors in or near the adrenal. In Fascicle 6, "Tumors of the Peripheral Nervous System," it is used to designate a hormonally active paraganglionic tumor in any location. Some other authors have included as paragangliomas tumors of the organ of Zuckerkandl, the glomus jugulare, the carotid body, and even the argentaffinomas of the appendix. The confusion in terminology encumbers the exchange of experience which can be so constructive in fields where no one pathologist's experience is enough. An agreement in nomenclature, even on an arbitrary basis, is helpful.

DEFINITION. This neoplasm is composed of pheochrome tissue, often accompanied by spasmodic or persistent hypertension, and is situated in or near the adrenal gland. The tumor is usually benign.

ORIGIN. The derivation of the cells of origin is given in figure 22. Thus the tumor is derived from primitive cells originating in the neural crest which can differentiate to form pheochromocytes.

INCIDENCE. About 210 authenticated cases of pheochromocytoma and paraganglioma have been reported up to 1948 (Brines and Jennings), and they are about equally divided between the two sexes. Although pheochromocytes have occurred in association with sympathetic elements as a mixture in tumors in infancy and early childhood, the age distribution of pheochromocytoma has been from 7 to 71 years, with the greatest incidence between 20 and 50 years. Brines and Jennings state that the tumor is in the adrenal in most of the cases, the right slightly more often than the left. Both adrenals may be involved in a small number of cases. Rarely, pheochromocytoma of the adrenal is accompanied by paraganglioma in other sites such as the organ of Zuckerkandl and retroperitoneal tissue. Furthermore, paraganglioma may be single or multiple, without adrenal tumor, in retroperitoneal tissues, in organs of Zuckerkandl, celiac ganglion, thoracic ganglia, and, according to one report, they may occur in the appendix. Association with neurofibromatosis is sufficiently frequent that it cannot be regarded as fortuitous (Rosenthal and Willis). Of the whole group, something in the order of 8 percent have been malignant.

CLINICAL FEATURES. If the tumor is large enough, it may be demonstrated by methods indicated previously (see p. 16) in the discussion of cortical tumors. The functional clinical phenomena are grouped in what is called the adrenal-sympathetic or adrenal-medullary syndrome. The most striking phenomenon is paroxysmal or spasmodic hypertension, and not infrequently persistent hypertension. Some authors have stated that this syndrome occurs in only half of the cases, but Mortell and Whittle maintain that hypertension, paroxysmal or sustained, is always present. Perhaps the size of the tumor has some bearing, because we have observed at autopsy tumors a few milimeters in dimension without clinical manifestations. Yet Spatt and Grayzel believe

that the size of the tumor is not significant in this respect. At any rate, the syndrome is not constant with paragangliomas in places other than the adrenal. Persistent hypertension occurs in a fairly large number of cases, and spasmodic hypertension may ultimately become continuous. Goldenberg, Snyder, and Aranow state that in Smithwick's series of lumbosacral sympathectomies in 1,000 cases of persistent hypertension, with exploration of the adrenals, the incidence of pheochromocytoma was 0.5 percent. This may well be low because of possible occurrence of paraganglioma elsewhere in the body.

Three forms are referred to by Spatt and Grayzel: (1) Malignant adrenal pheochromocytoma with metastasis (this can be accompanied by hypertension); (2) benign adrenal pheochromocytoma with hypertension, either spasmodic or persistent; (3) benign adrenal pheochromocytoma found incidentally at autopsy, with no clinical signs or symptoms. However, Palmer and Castleman maintain that patients in this last group may die suddenly as the result of slight trauma or even a minor surgical operation.

Attacks of spasmodic hypertension are usually of abrupt onset, sometimes without known stimuli, but more often precipitated by emotional upsets, undue physical effort, heavy meals, manual manipulation of the tumor in clinical examination or at operation, an unusual position of the body in which the tumor mass is automatically compressed, as well as hyperventilation, and perhaps anesthesia (fig. 35). Cahill speaks of pounding headache, pronounced cardiac palpitation, epigastric distress, vasoconstriction of hands and feet, and often a sense of impending death. Grollmann summarizes the phenomena as "instability of the sympathetic nervous system, hypertension or paroxysmal hypertension, glycosuria, periodic attacks of tachycardia, vasoconstriction and vasodilation of the peripheral vessels (as evidenced by pallor and flushing), headache, nausea, vomiting, sensations of constriction of the epigastrium and a susceptibility to shock." The blood pressure in the attacks is high and may reach figures of 300/200 mm. Hg. (Hyman and Mencher). The oscillometer shows a fall in the extremities and the dermograph a fall in skin temperature. Electrocardiograms are not characteristic except that in prolonged cases there may be left ventricular preponderance. Metabolic rate is increased. Glycosuria, albuminuria, and even hematuria may occur in the attack and disappear in the interval. Occasionally, true diabetes is an accompaniment and is relieved by removal of the tumor. The heart may be enlarged and arteriosclerosis may be pronounced.

In the fundus of the eye there may be spasmodic constriction of arteries alone or with other changes such as blurring of disc margins, "cotton-wool" patches, and hemorrhage. Bruce states that "the findings cannot be differentiated ophthalmologically from those encountered in the so-called 'essential hypertension.'" However, these lesions are found in those cases of pheochromocytoma with persistent hypertension or spasmodic hypertension in which the

blood pressure does not fall to normal in the intervals. They do not accompany spasmodic hypertension with complete remission between attacks. The ocular lesions usually resolve after removal of the tumor.

The attacks last from a few minutes to 16 hours or more and are followed by prostration. Rarely, death results from shock, cardiac failure, or even cerebral hemorrhage.

The phenomena are like those of an overdose of epinephrine. Assays by various methods have usually demonstrated relative and total increase in the amount of epinephrine in the tumor over that of the adrenal gland. Assay methods have been compared by Pinniger and Brown in reporting a pheochromocytoma which weighed 1,200 grams. Crystalline epinephrine in large amount has been recovered from a pheochromocytoma by Kelly, Piper, Wilder, and Walters. A pressor substance, probably of the nature of epinephrine, has been demonstrated by Beer, King, and Prinzmetal in the blood during an attack. Thus, although other mechanisms may also be involved, as suggested by Spatt and Grayzel, the effects almost certainly result from an excess output of epinephrine. The work of Goldenberg, Farber, Alston, and Chargaff indicates that the principal active component producing this type of hypertension is norepinephrine (arterenol). Norepinephrine is produced in the adrenal medulla coetaneously with epinephrine. Its structural formula and mechanism of production have not been determined.

Various clinical tests have been applied. Most of these deal with epinephrine stimulants and provoke attacks or simply elevation of blood pressure. Included are histamine, ergotamine tartrate, tetraethylammonium bromide, and "mecholyl." There is also increased pressure with the cold pressor test. In support of the evidence that the hypertension, spasmodic or persistent, is due to epinephrine, is the temporary fall in blood pressure by injections of epinephrine antagonists or adrenolytic agents. Goldenberg, Snyder, and Aranow used two of the benzodioxanes, and finally preferred 933 F (piperidylmethyl benzodioxane). After removal of the tumor the test is negative. Cahill employed this test successfully. This fall of pressure does not occur in essential hypertension. Confirmation of these tests is needed. Their application as a screening test to all cases of hypertension without clinical suspicion of tumor is too new to be appraised.

GROSS. The tumor of the adrenal is usually small with a diameter in the order of 1 to 10 centimeters. Larger sizes occur and Soffer reports one which weighed 2,000 grams. The small tumors are poorly defined, but those up to 10 cm. or even more appear to be encapsulated (figs. 36, 37, pl. IV). However, the capsule often is that of the adrenal because microscopically there is usually an intermingling of cortical cells at the margin. Often there are segments of yellow cortex at the border of the tumor. The outer surface varies from pale gray or pink to dusky brown. The solid tumors are fairly firm but

Plate IV. Drawing of Two Pheochromocytomas.

A. Cross section of tumor removed at autopsy from a patient with persistent hypertension. A. F. I P. Neg. Acc. No. 218755–C 2.

B. Outer aspect of pheochromocytomas from a patient with spasmodic hypertension. The larger tumor has adrenal cortical tissue at the upper part of the illustration. The capsule is thin in several places but not penetrated. The smaller tumor was near the renal artery. Whether the latter is a metastasis or a separate tumor is not known. Removal of these tumors did not cure the spasmodic hypertension. Patient followed for four years, but subsequent story is not known. A. F. I. P. Neg. Acc. No. 218755–C1.

C. Cross section of larger tumor in B. Note brown color of tumor, pale yellow masses of necrosis and a focus of hemorrhage. A. F. I. P. Neg. Acc. No. 218755–C1.

Plate IV.

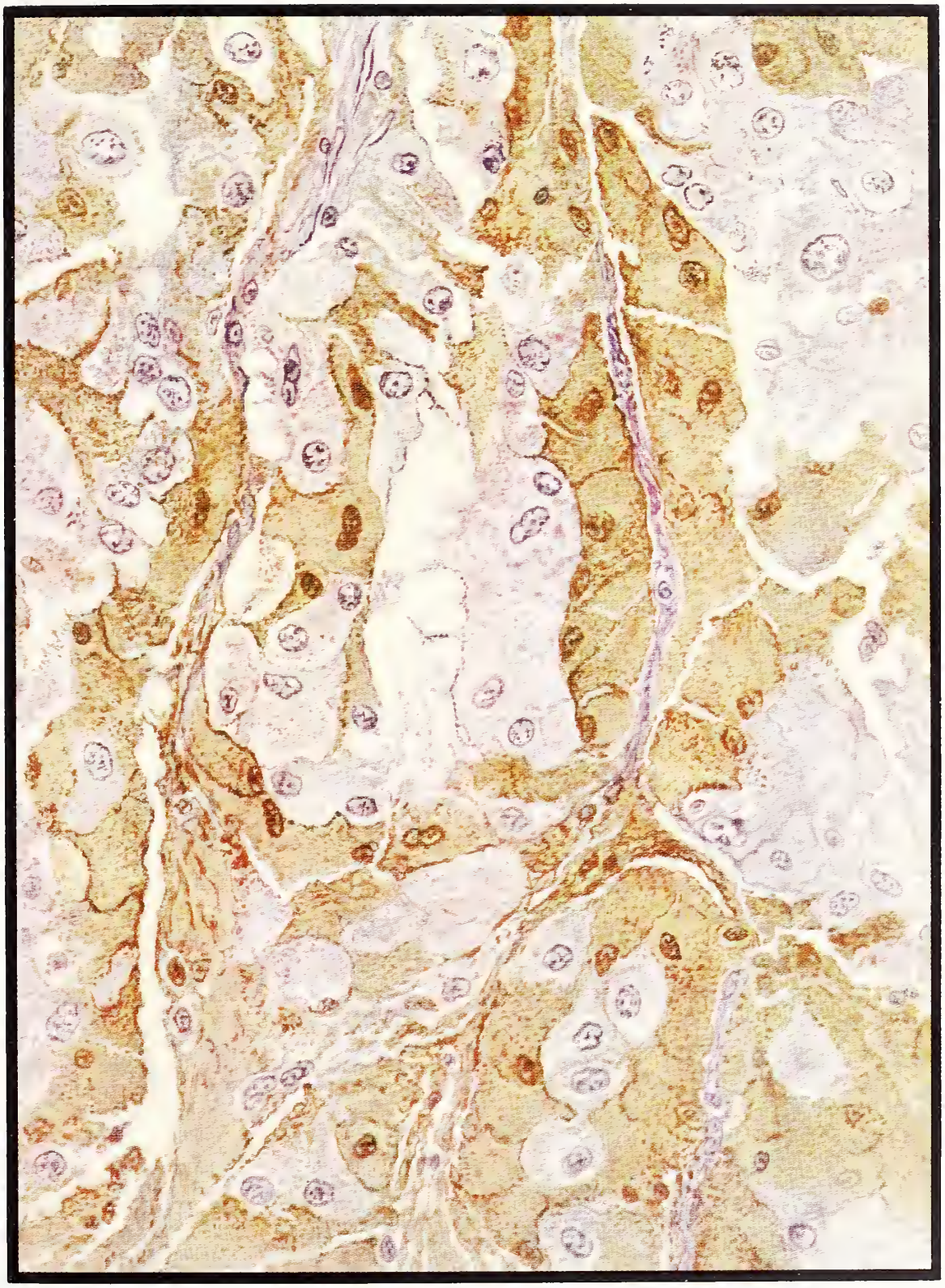

Plate V. Colored photomicrograph of pheochromocytoma treated with chromate. Note that some cells are not chromated, and that the brown granules vary in size and in number in the cyoto-plasm of the chromated cells. A. F. I. P. Neg. Acc. No. 218755–C6.

if cystic may be somewhat elastic. The mass cuts with little resistance. The cross section is moist, bulges slightly, bleeds moderately, and may be somewhat friable. The cross section may be mottled by foci of yellow necrosis and by hemorrhages. Cysts with either shaggy or smooth walls may vary in size and contain clots of blood or slightly granular fluid often tinged brown. Colorless fluid, such as formalin, in which tissue is fixed, often becomes brown after a day or so. As indicated above, the tumors may be multiple.

MICROSCOPIC. Most of the cells are polygonal or even fusiform, accompanied by others which are spherical or elliptical. Pleomorphism may be conspicuous even in tumors known to be benign. The cells are large and the cytoplasm abundant, yet cellular outline may not be sharp. The cytoplasm is acidophilic and slightly granular and often contains pigment granules. As a rule, these give a negative chemical reaction for iron and are not dissolved by hydrogen peroxide. The nucleus may be centrally or eccentrically situated, is fairly large, spherical or ovoid, and is vesicular with a fine chromatin network, and with a nucleolus which is often amphophilic. Multinucleated cells occur, but mitotic figures are rare (figs. 38, 39, 40, 41, 42).

In addition to pheochromocytes and pheochromoblasts, sympathoblasts and ganglion cells may be encountered. The amount of stroma is variable and yet may be so distributed that groups of cells are divided into an alveolated pattern (fig. 39). Capillaries and larger vessels may be numerous. Necrosis and hemorrhage may be slight or extensive. Tumor cells in blood vessels are not indicative of malignancy.

We hold that a diagnosis of pheochromocytoma is not valid without a positive chromaffin reaction. Fixatives containing chrome salts are desirable, but formalin fixed material may be treated for 24 hours, preferably with Kohn's solution (3.5 percent potassium dichromate in 10 percent formalin) as recommended by Rosenthal and Willis. In the sections the positive cells are stained brown. The stain is in the cytoplasm between the granules rather than in the granules themselves (pl. V). The positive cells are usually in small clusters, surrounded by a delicate stroma, but often only the peripheral cells in the clusters are chromated. It is possible that the nonreactors are pheochromoblasts. Other methods are also suitable. The Schmorl technique includes staining by Giemsa solution. The nuclei are stained blue and the cytoplasm of pheochrome cells a deep green. Gomori recommends the use of azocarmine on formalin fixed material. The nucleus stains faintly, the nucleolus is red, and the cytoplasm contains granules stained bluish violet.

The exact chemistry of the tinctorial responses of both the cytoplasmic granules and of the chromaffin reaction should be given precise study. Dietrich and Siegmund, on hypothetical grounds, suggest that the granules are made of epinephrine or a precursor, and that as the granules enlarge they lose their color and burst from the cells to form intercellular lakes which subsequently

become stained brown. In the usual specimen these changes cannot be identified. Brines and Jennings report that melanin granules may also be found. This will be referred to in the section on melanoma of the adrenal. Reviewing the story of the chromaffin reaction, Brines and Jennings state that it is a nonspecific reaction between epinephrine or various other substances and strong oxidizing agents. Although cells of the adrenal medulla and of the pheochromocytoma give a strong chromaffin reaction, this does not specifically identify the presence of epinephrine in the cell. So there remains a gap between the chemistry and histology of this interesting tumor.

DIFFERENTIAL DIAGNOSIS. The morphology and arrangement of cells suggest adrenal medulla. Brines and Jennings believe a diagnosis can be made on that basis. However, polygonal cells may be numerous in cortical adenoma, and cells which resemble those of the cortex occur in pheochromocytoma. Our opinion is that special techniques indicated above are necessary in order to distinguish between medullary and cortical tumors. Clinical correlation may be helpful, but an occasional pheochromocytoma perhaps may not be functional. Diagnosis based on morphology and tinctorial properties is desirable.

TREATMENT. Surgical removal has been successful in many cases. Cahill recommends anesthesia by tribromethanol as less likely to produce attacks of hypertension. The approach is preferably by the lumbar route unless the tumor is large. If the tumors are multiple, a multiple, transperitoneal removal is required. Extreme care should be taken in surgical manipulations lest an intolerable amount of epinephrine be expressed into the circulation. Continuous operative and frequent postoperative readings of blood pressure are needed; for, paradoxically, the opposite adrenal may have become atrophic, and, after the ligation of the tumor pedicle, a profound fall of blood pressure may occur and be prolonged. Epinephrine should be ready and may have to be given in continuous infusion in salt solution. Administration of cortical extract may be necessary.

Pheochromoblastoma. Synonyms and Related Terms: Phaiochromoblastoma (Lat.); chromaffinoblastoma; malignant chromaffinoma; malignant pheochromocytoma.

DEFINITION. This term is sometimes used to designate malignant forms of pheochromocytoma, as evidenced by invasion of the capsule, direct extension, and metastases. However, the distinction in neoplasia between pheochromocytes and pheochromoblasts is difficult or impossible to make.

ORIGIN. Whether this tumor originates as such or represents a change in biological properties of a pheochromocytoma is not certain.

INCIDENCE. About 8 percent of pheochromic tumors are malignant. The number of cases collected so far does not justify any conclusions as to age and sex incidence, but it appears to affect younger age groups.

CLINICAL FEATURES. It has been said that the clinical phenomena described in connection with benign pheochromocytoma are less likely to occur with the malignant tumor. However, this view is subject to confirmation by further study. When endocrine manifestations occur, they cannot be distinguished from those of the benign tumor. In rare instances, metastasis may be the first sign of the "occult" adrenal tumor; in a case reported by Spatt and Grayzel, with numerous cerebral metastases, the symptoms and signs of intracranial tumor dominated the clinical picture. Destruction may be great enough to cause adrenal insufficiency.

DESCRIPTION. The tumor is like the benign form except that the capsule is not complete, and there may be direct extension to surrounding structures. Metastasis is principally by way of the blood stream and may be exceedingly widespread, as in the case reported by McGavack and associates.

MICROSCOPIC. The features are like those of pheochromocytoma. It is generally agreed that on the basis of histology alone, a distinction cannot be made between benign and malignant forms, except for demonstration of invasion of the capsule. Stout finds that the presence of tumor cells in the abundant blood vessels is not a criterion of malignant neoplasm (see Fascicle 6, p. 49, "Tumors of the Peripheral Nervous System"). Wahl and Craig suggest a special disposition to hemorrhage, calcification, and osseous metaplasia in the tumor.

TREATMENT. Nothing is known to be effective.

References

Beer, E., King, F. H., and Prinzmetal, M. Pheochromocytoma with demonstration of pressor (adrenalin) substance in the blood preoperatively during hypertensive crises. Ann. Surg., 106: 85–91, 1937.

Brines, O. A., and Jennings, E. R. Paragangliomas. Review of subject and report of five original cases. Am. J. Path., 24:1167–1197, 1948.

Bruce, G. M. The ocular fundus in pheochromocytoma of the adrenal gland. Report of 3 cases. Tr. Am. Ophth. Soc., 45: 201–228, 1947.

Cahill, G. F. Pheochromocytomas. J. A. M. A., 138:180–186, 1948.

Dietrich, A., and Siegmund, H. Die Nebenniere und das chromaffine System (Paraganglien, Karotisdrüse, Steissdrüse). In: Henke, F. and Lubarsch, O. Handbuch der speciellen pathologischen Anatomie und Histologie, Vol. VIII, pp. 951–1089. Berlin: Springer, 1926.

Friedman, N. B., and Ash, J. E. Atlas of Genitourinary Pathology. Washington, D. C.: American Registry of Pathology, 1946.

Goldenberg, M., Farber, M., Alston, E. J., and Chargaff, E. C. Evidence for the occurrence of nor-epinephrine in the adrenal medulla. Science, 109: 534–535, 1949.

Goldenberg, M., Snyder, C. H., and Aranow, H., Jr. New test for hypertension due to circulating epinephrine. J. A. M. A., 135: 971–976, 1947.

Gomori, G. Staining of chromaffin tissue. Am. J. Clin. Path. (Tech. Sect.), 10:115–117, 1946.

Grollman, A. The Adrenals. Baltimore: The Williams and Wilkins Company, 1936.

Hyman, A., and Mencher, W. H. Pheochromocytoma of the adrenal gland. J. Urol., 49: 755–776, 1943.

Kelly, H. M., Piper, M. C., Wilder, R. M., and Walters, W. Case of paroxysmal hypertension with paraganglioma of the right suprarenal gland. Proc. Staff Meet. Mayo Clin., 11: 65–70, 1936.

McGavack, T. H., Benjamin, J. W., Speer, F. D., and Klotz, S. Malignant pheochromocytoma of the adrenal medulla (paraganglioma). Report of a case simulating carcinoma of the adrenal cortex with secondary adrenal insufficiency. J. Clin. Endocrinol., 2: 332–338, 1942.

Mortell, E. J., and Whittle, J. P. Pheochromocytoma: Case report with certain observations on pathologic physiology. J. Clin. Endocrinol., 5: 396–402, 1945.

Palmer, R. S., and Castleman, B. Paraganglioma (chromaffinoma, pheochromocytoma) of the adrenal gland simulating malignant hypertension. New England J. Med., 219: 793–796, 1938.

Pinniger, J. L., and Brown, J. B. Adrenal pheochromocytoma. Arch. Path., 47: 557–565, 1949.

Rosenthal, D. B., and Willis, R. A. The association of chromaffin tumours with neurofibromatosis. J. Path. & Bact. 42: 599–603, 1936.

Soffer, L. J. Diseases of the Adrenals. 2d ed. Philadelphia: Lea & Febiger, 1948.

Spatt, S. D., and Grayzel, D. M. Pheochromocytoma of the adrenal medulla. Am. J. M. Sc., 216: 39–50, 1948.

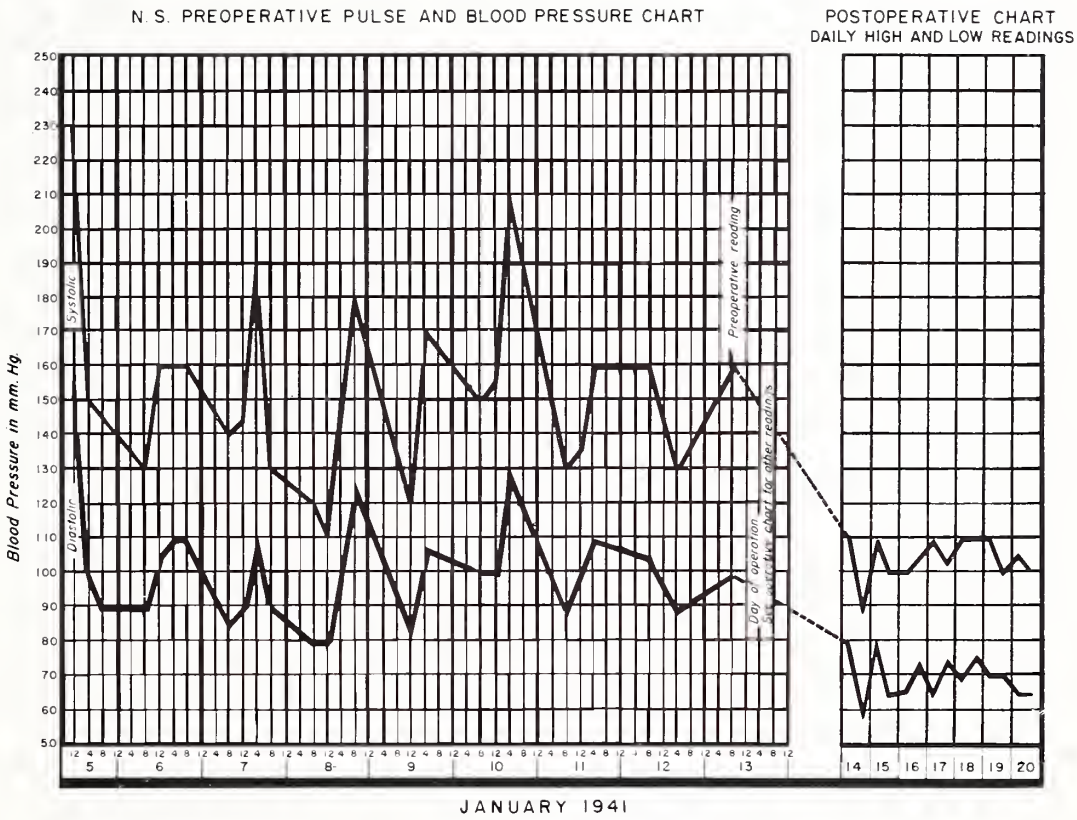

Figure 35. Chart of preoperative and postoperative pulse and blood pressure in a case of pheochromocytoma in a white female, aged 26. Same case as plate IV. (Patient of Dr. James Joelson.) A. F. I. P. Neg. Acc. No. 218755–32.

Figure 36. Outer aspect of pheochromocytoma of adrenal from a white female, aged 30. Capsule is complete and a segment of cortex is attached at the right. (Patient of Dr. John Williams.) A. F. I. P. Neg. Acc. No. 218755–33.

Figure 37. Cross section of pheochromocytoma of a white male, aged 16. The tumor is soft, friable, vascular, and necrotic. The central pale necrotic mass is partly walled off by fibrosis. A. F. I. P. Neg. Acc. No. 218755–34.

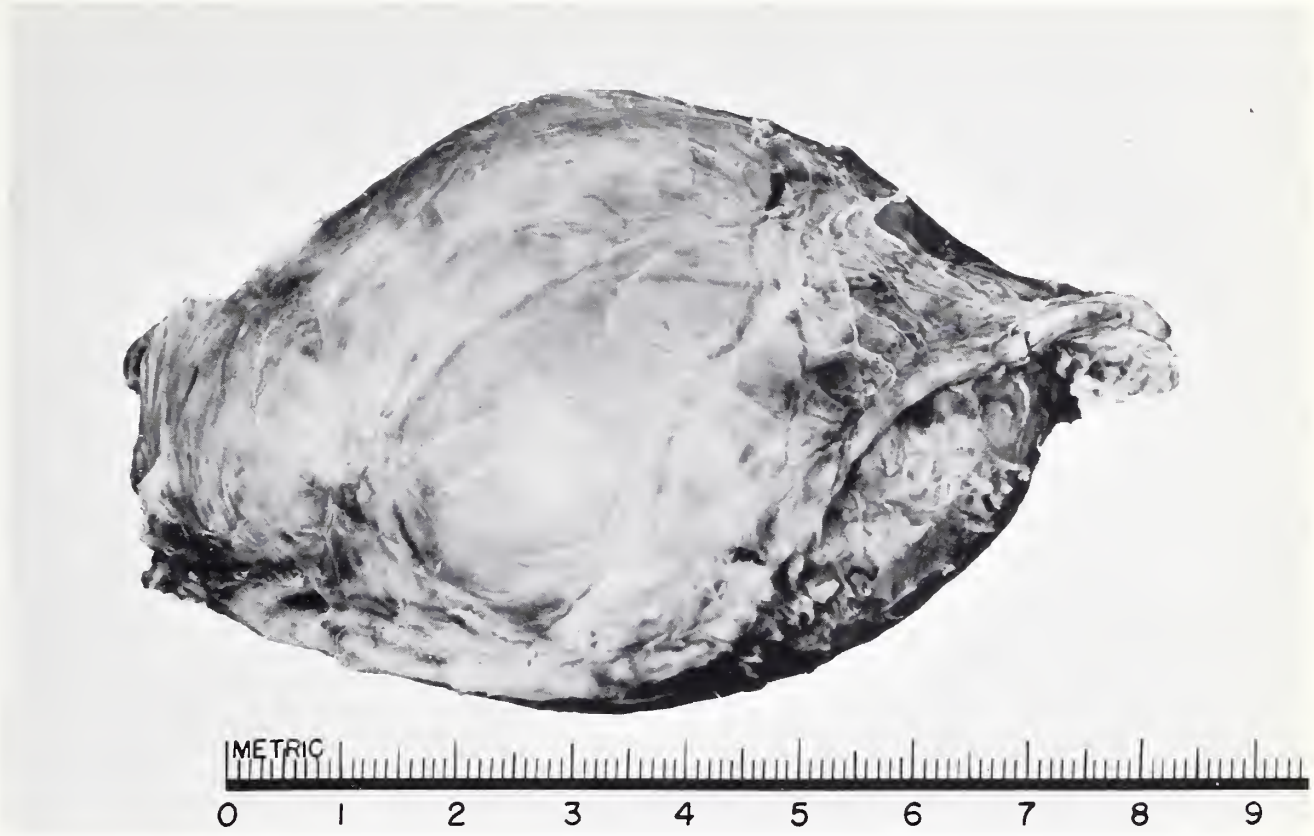

Fig. 36

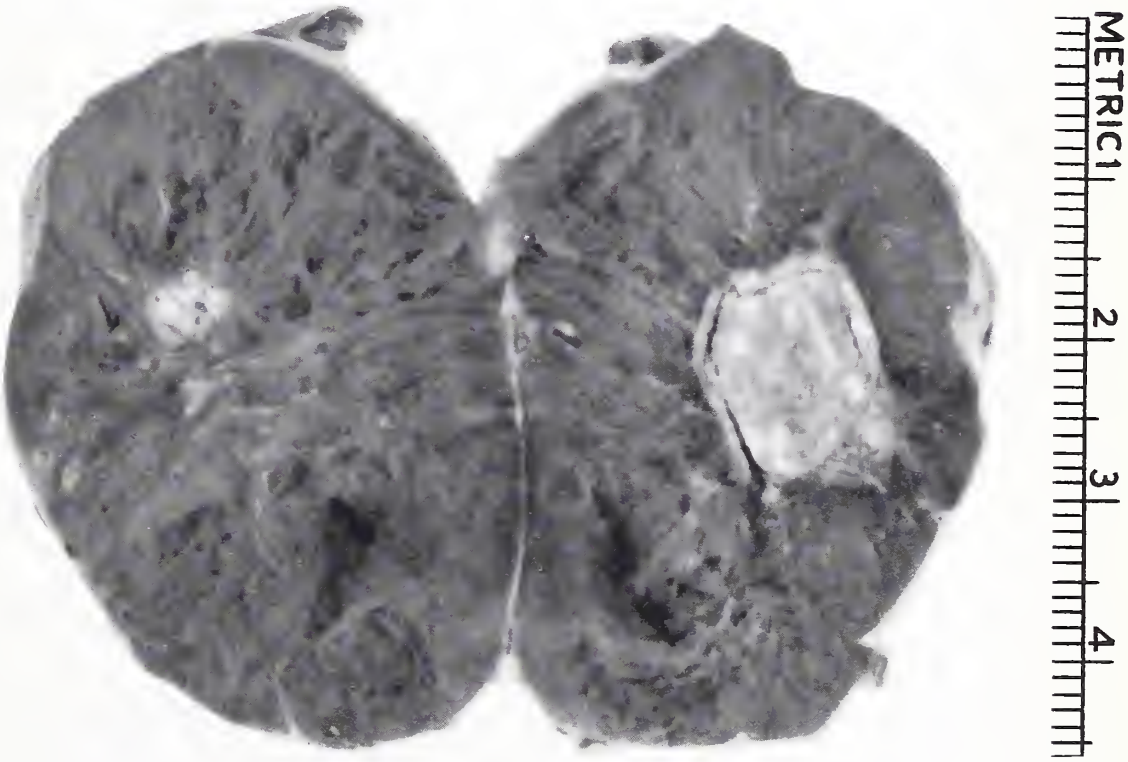

Fig. 37

Figure 38. Photomicrograph of margin of pheochromocytoma, without invasion of capsule. × 250. Same case as figure 37. A. F. I. P. Neg. Acc. No. 218755–38.

Figure 39. Photomicrograph of pheochromocytoma. The clusters of tumor cells are separated by delicate strands of connective tissue, producing an alveolated structure. The patient, a white male aged 56 years, died of bronchopneumonia following sympathectomy for hypertension. The tumor was discovered at autopsy. × 200. A. F. I. P. Neg. Acc. No. 218755–39.

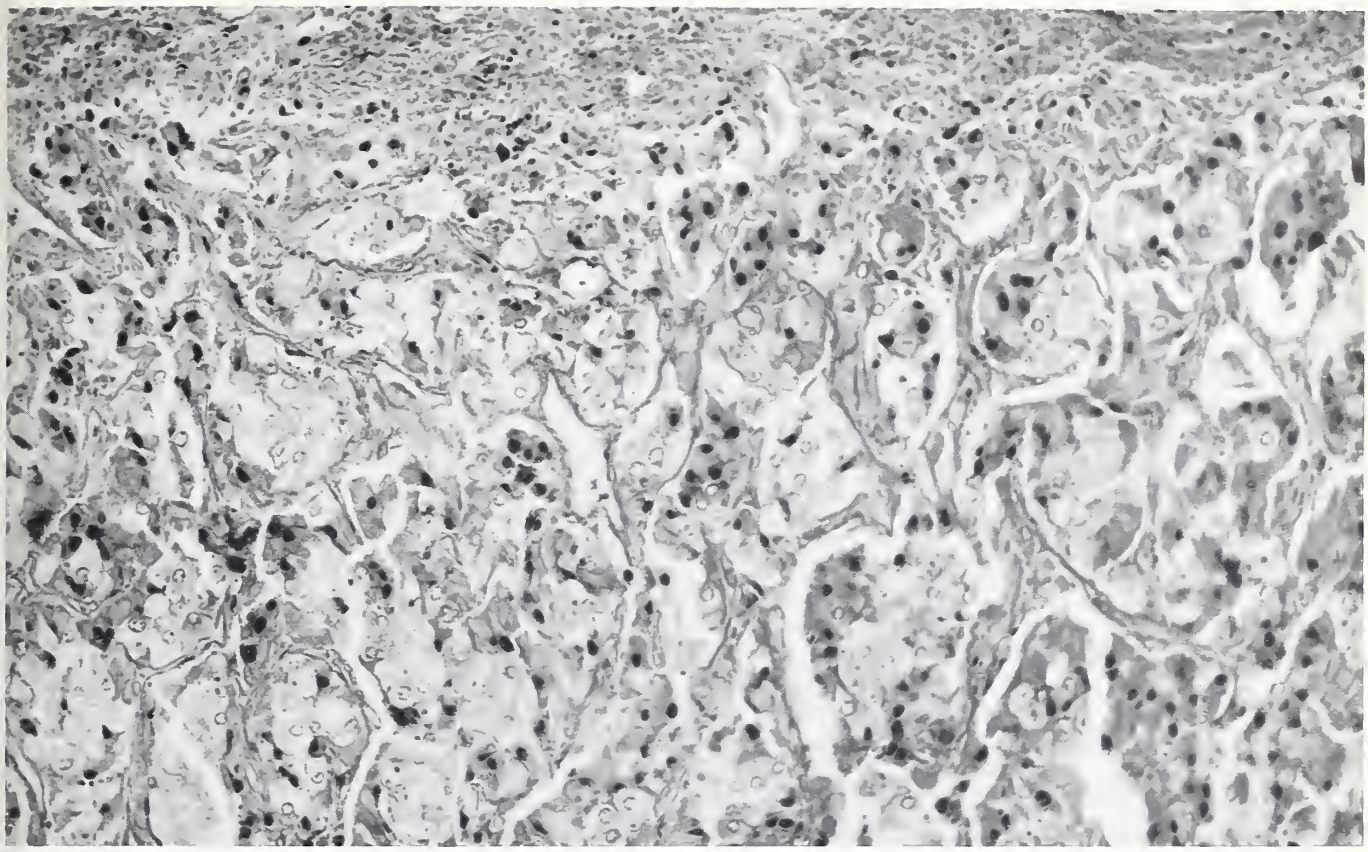

Fig. 38

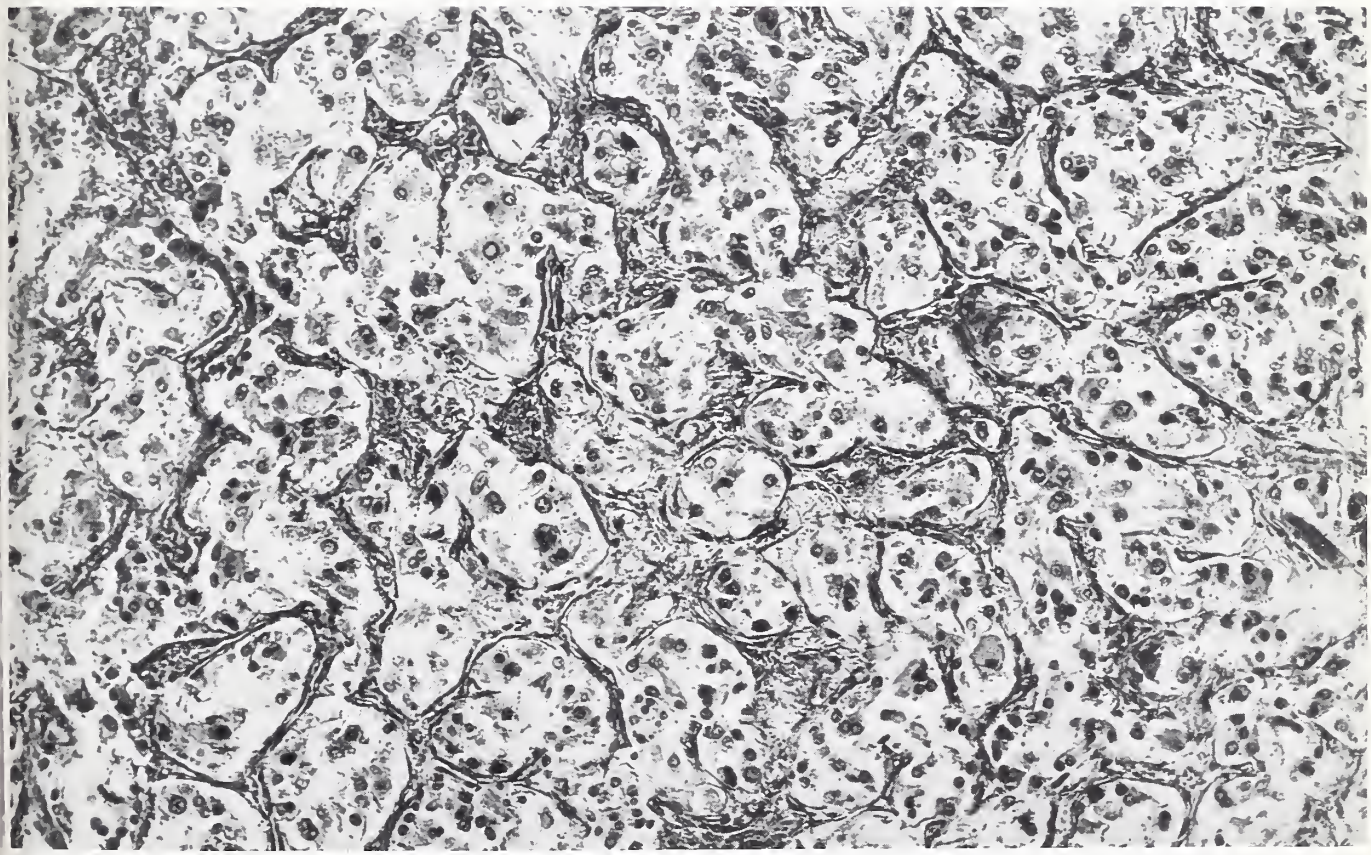

Fig. 39

Figure 40. Photomicrograph of vascular pheochromocytoma with polymorphous cytology showing elongated, polygonal, and spherical cells. × 316. Same patient as figure 35. A. F. I. P. Neg. Acc. No. 218755–35.

Figure 41. Photomicrograph of pheochromocytoma (pheochromoblastoma) from a white female, aged 30. Elongated and polygonal cells with granular cytoplasm and pigment granules. × 1140. Grossly, capsule was invaded. (Patient of Dr. James Joelson.) A. F. I. P. Neg. Acc. No. 218755–36.

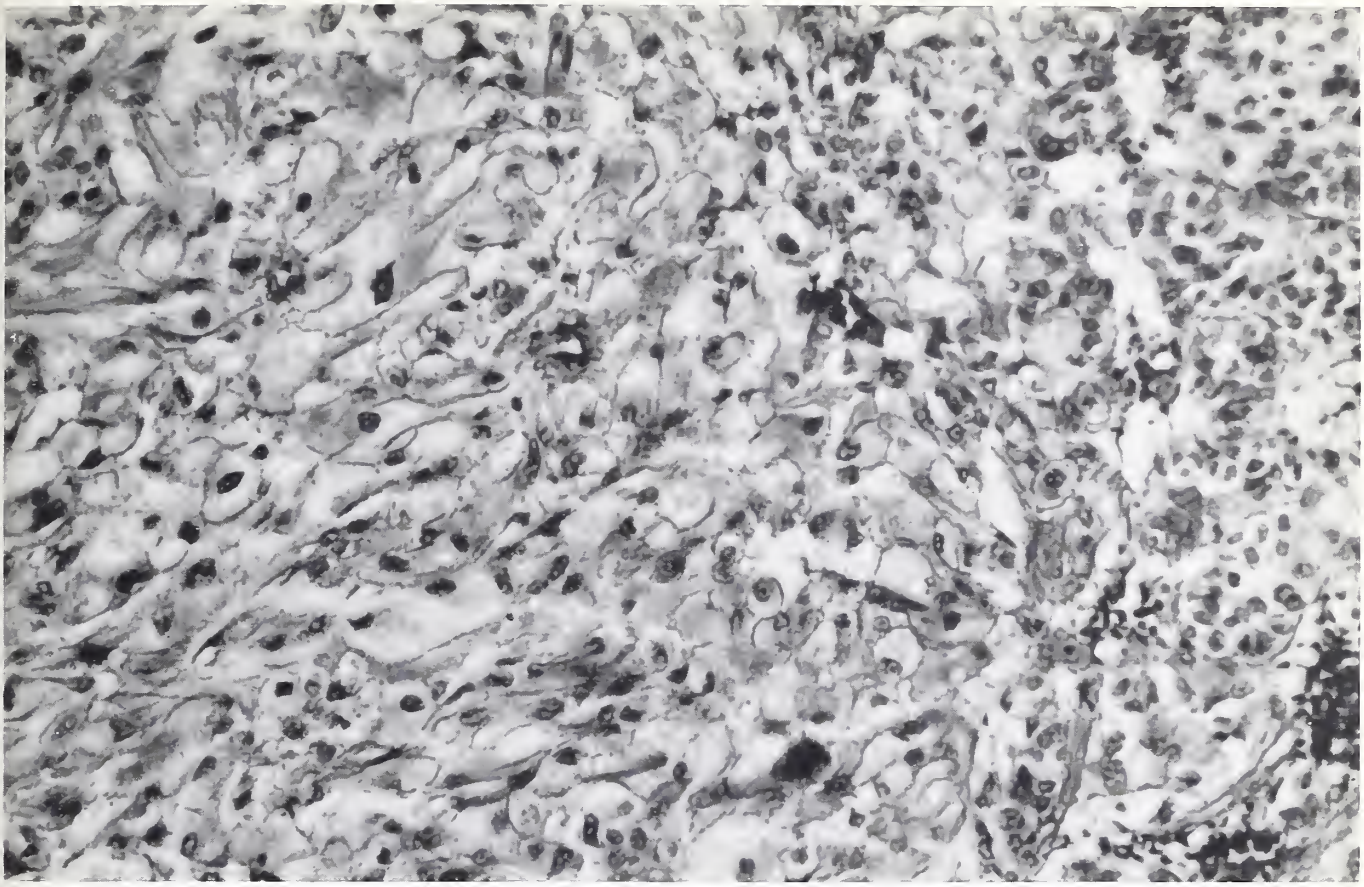

Fig. 40

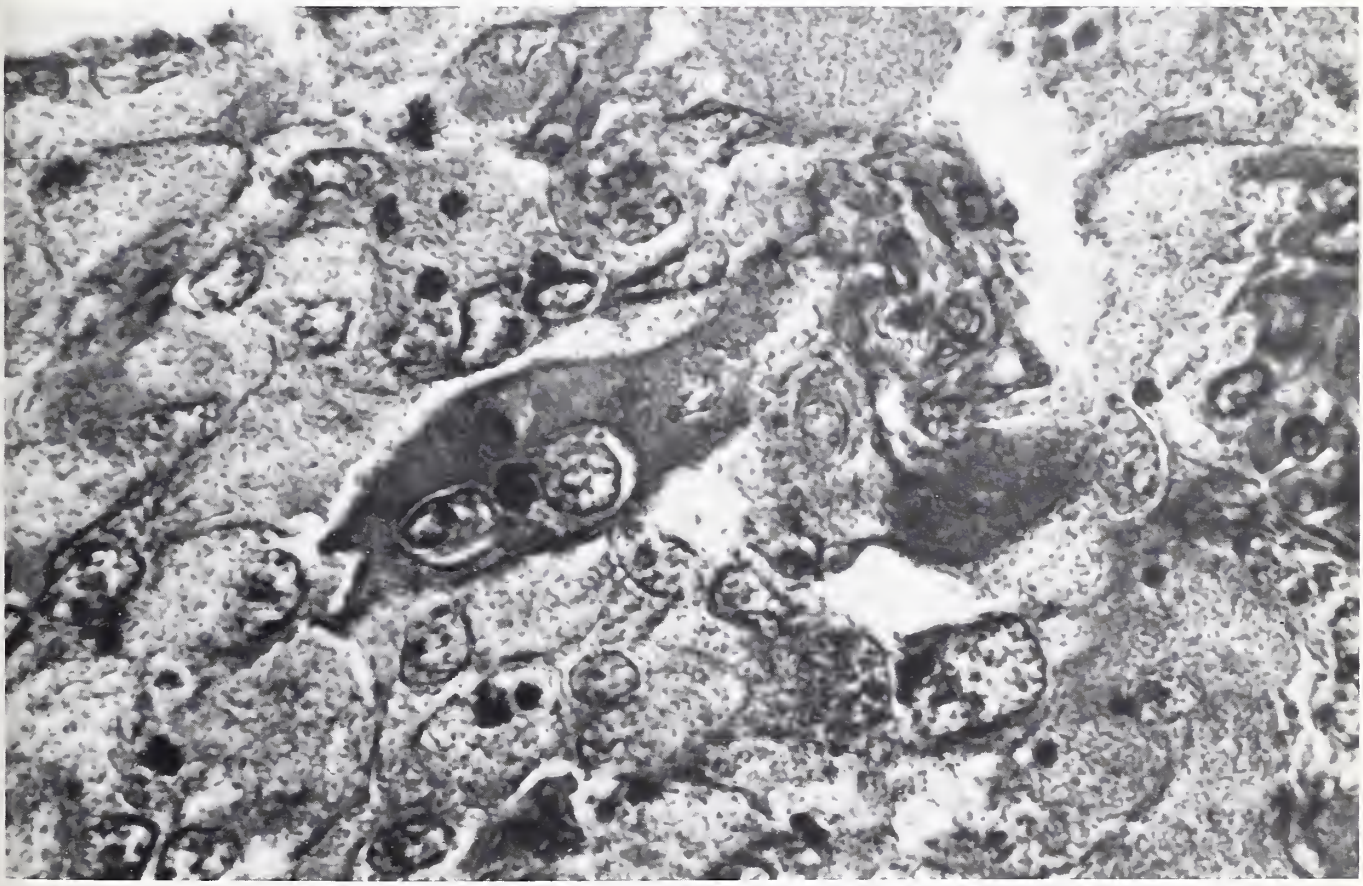

Fig. 41

Figure 42. Photomicrographs of different fields in pheochromocytomas to show different cellular types. (Contributed by Dr. Eleanor M. Humphrey to "Atlas of Genitourinary Pathology", American Registry of Pathology, p. 213, 1946.) A. F. I. P. Neg. Acc. No. 114159.

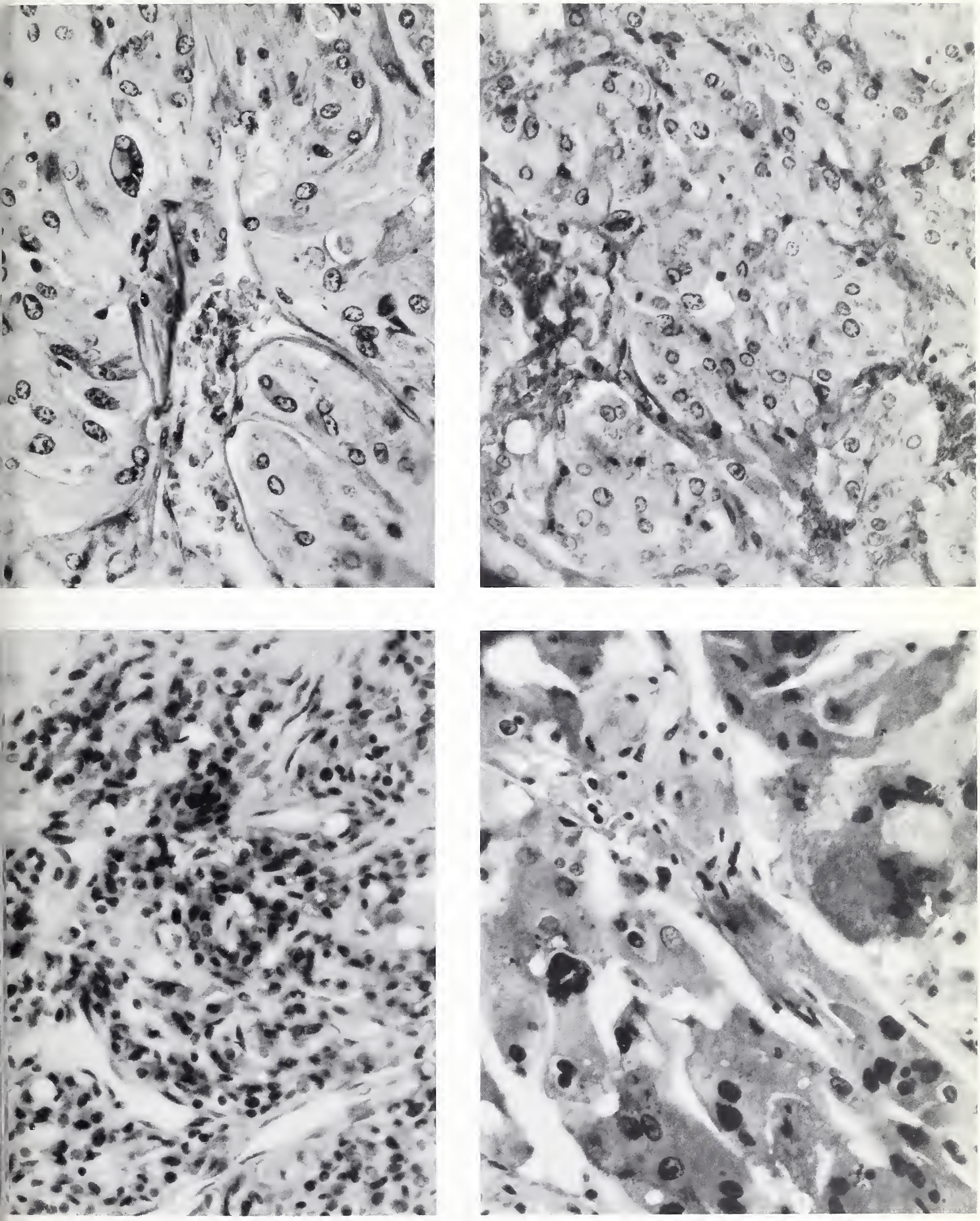

Fig. 42

Figure 43. Bilateral metastatic carcinoma of adrenals, with complete destruction of those organs but without extension into kidneys. A. F. I. P. Neg. Acc. No. 51498.

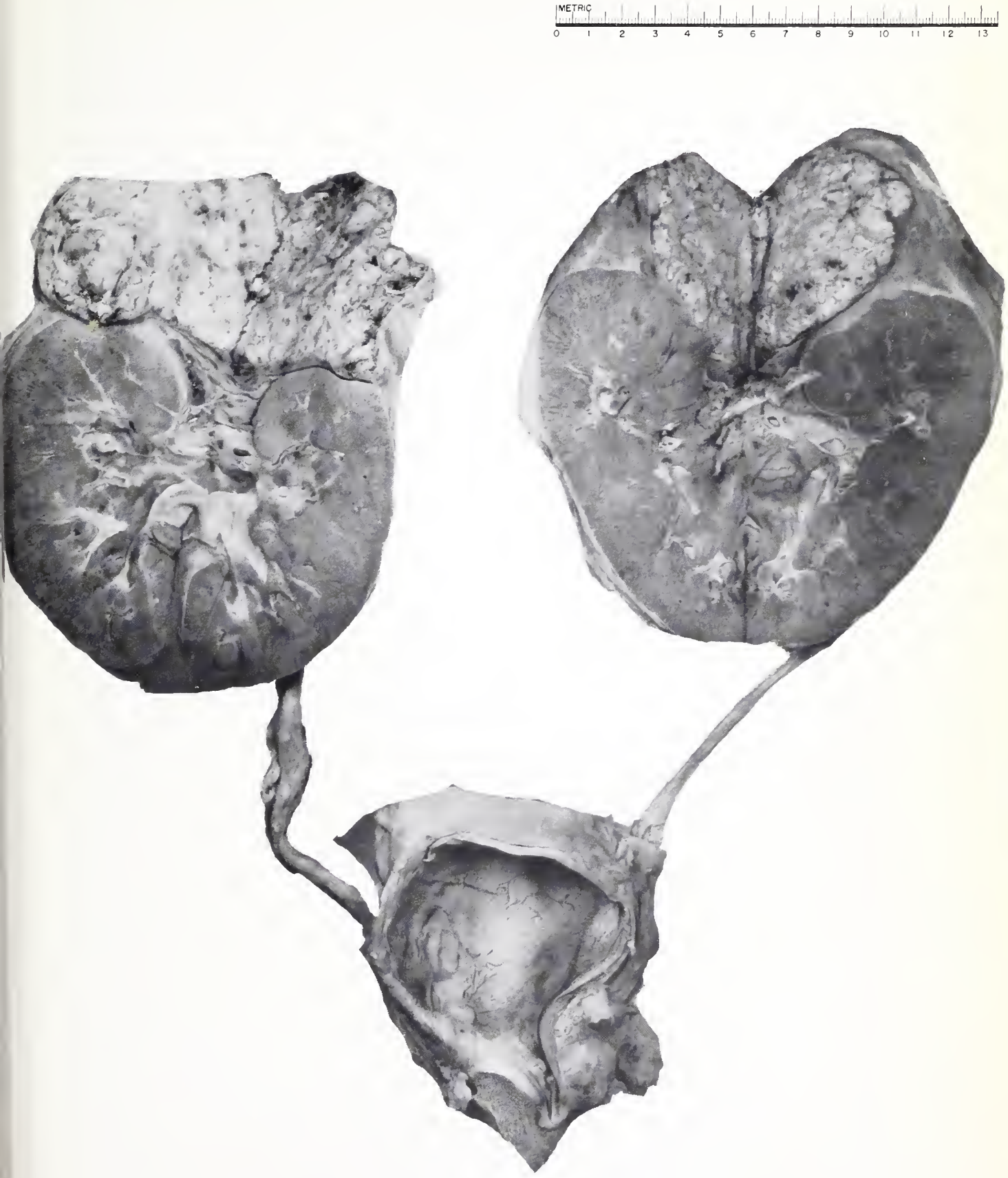

Fig. 43

PHEOCHROMOCYTOMA

PROFESSIONAL NOTES AND FINDINGS

MELANOMA

Synonyms and Related Terms: Melanoma (Lat.); black tumor; chromatophoroma; melanoblastoma; melanocarcinoma; melanocytoblastoma; melanoepithelioma; melanosarcoma; naevocarcinoma; pigmented melanoma.

DEFINITION. This is a primary malignant neoplasm of the adrenal composed principally of melanoblasts. The term melanoblast is restricted to those cells that produce melanin. Melanophores are the cells that contain melanin without producing it. Reserve cells are undifferentiated prospective melanoblasts devoid of or containing scant pale pigment. These are the terms accepted by the New York Academy of Sciences in its 1948 symposium on the "Biology of Melanomas."

ORIGIN. Melanoblasts of skin originate in the neural crest and evidently the same is true of similar cells which have been observed in the adrenals of man and other animals. Although peripheral nerve tumors may contain melanin, as reported by Brines and Jennings, tumors of this sort are recognized by their cytology as different from melanoma. The same applies to deeply pigmented cortical adenomas. There is no evidence that a progonoma such as the cutaneous nevus occurs in the adrenal.

INCIDENCE. Many have expressed doubt as to the occurrence of a primary melanoma of the adrenal, and have suggested that such tumors are metastatic. Up to 1934, Willis found no case reported which would withstand criticism. In 1946, Knisely and Baggenstoss reported a case of melanoma of the left adrenal with widespread metastasis in which there was no lesion of skin, eye, anus, rectum, or meninges. They state that "it is fairly certain that there are not more than 11 authenticated cases reported," and include some which were doubtful in the opinion of Willis.

CLINICAL FEATURES. There may be the wasting, anemia, and other features of malignant tumors. Pain may occur in the flank, but this may be due to direct invasion or metastasis. Pyelograms and air studies might help in localizing a tumor.

GROSS. The primary tumor reported by Knisely and Baggenstoss measured 8.5 x 5.5 x 4.5 cm. and destroyed the adrenal. It was brownish black, soft, not friable, and not completely encapsulated. Foci of necrosis were present. Metastasis was widespread.

MICROSCOPIC. The cells are of ovoid or spindle form with an abundant cytoplasm often poorly defined and with a somewhat vesicular nucleus. Stroma

is not prominent and vascularity is not great. The cytoplasm contains granules of opaque pigment sometimes in such great quantities as to obscure the nucleus (fig. 44). This pigment must be differentiated from hemosiderin, lipochromes, and the granules in pheochromocytes. Baker, in a report of a pigmented adenoma of the adrenals, gives a table of differential staining. Melanin does not stain for iron, is not dissolved by fat solvents, is bleached by hydrogen peroxide, and becomes darkened by 5 percent aqueous silver nitrate. Characteristic reaction with dopa has not been established. The relationship to tyrosin and epinephrine has been discussed in several papers without any satisfactory conclusions.

As with other varieties of melanoma, the metastases vary greatly in the content of pigment.

DIFFERENTIATION. The tumor is identified as primary in part by exclusion of other possible primaries, by cytology, and by the special character of the pigment. Deeply pigmented cortical adenomas have been mistaken for melanoma.

TREATMENT. There is no specific therapy.

References

Baker, M. R. A pigmented adenoma of the adrenal. Arch. Path., 26: 845–852, 1938.

Brines, O. A., and Jennings, E. R. Paragangliomas. Review of subject and report of five original cases. Am. J. Path., 24: 1167–1188, 1948.

Gorden, M., Algire, G. H., and others. The Biology of Melanomas, New York Academy of Sciences, Special Publications, Vol. IV. p.16. New York: The Academy, 1948.

Knisely, R. M., and Baggenstoss, A. H. Primary melanoma of the adrenal gland. Arch. Path., 42: 345–349, 1946.

Willis, R. A. The Spread of Tumors in the Human Body. London: J. & A. Churchill, 1934.

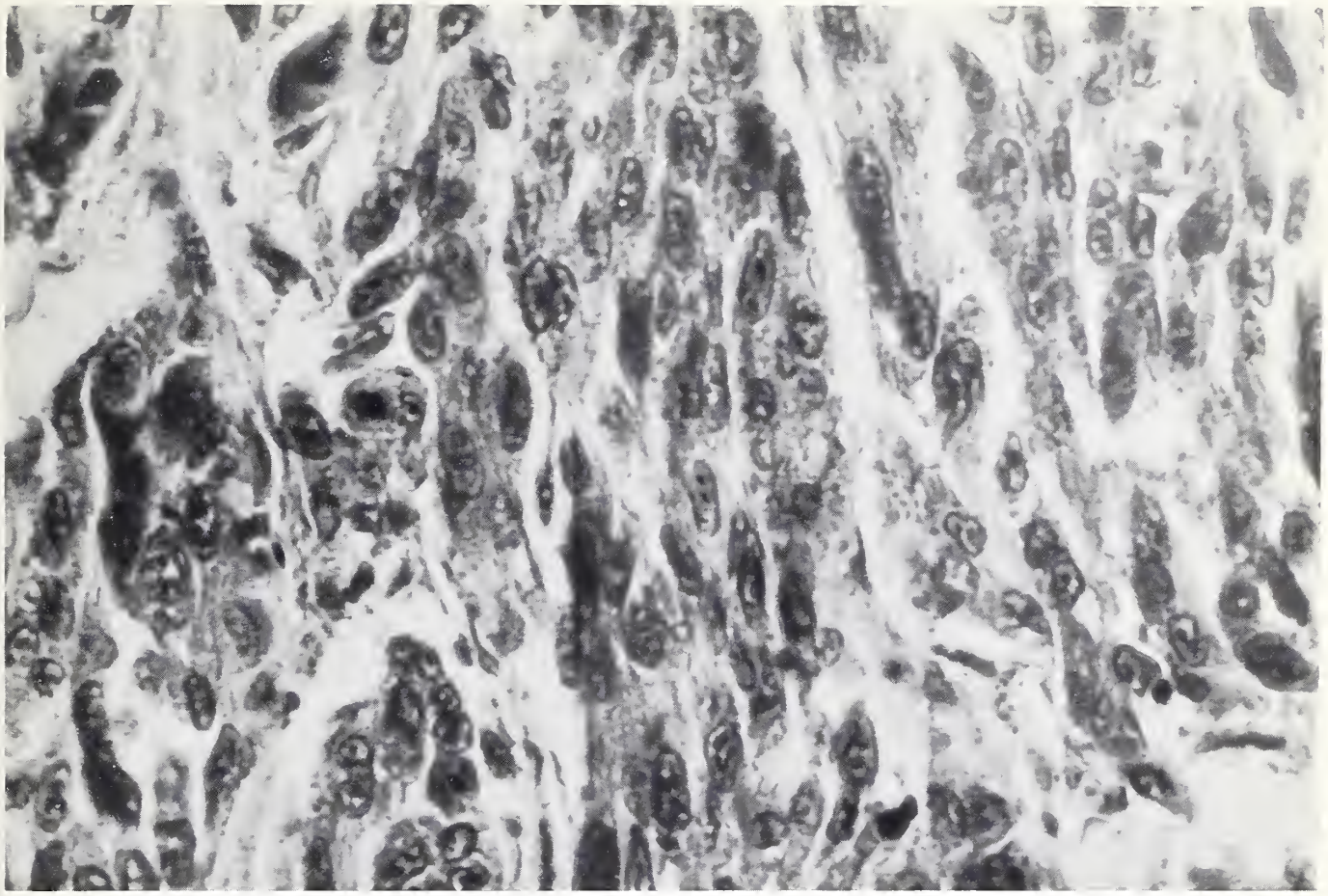

Figure 44. Photomicrograph of melanoma metastatic to adrenal. Note arrangement and form of cells and pigment granules in cytoplasm. A. F. I. P. Neg. Acc. No. 50813–2.

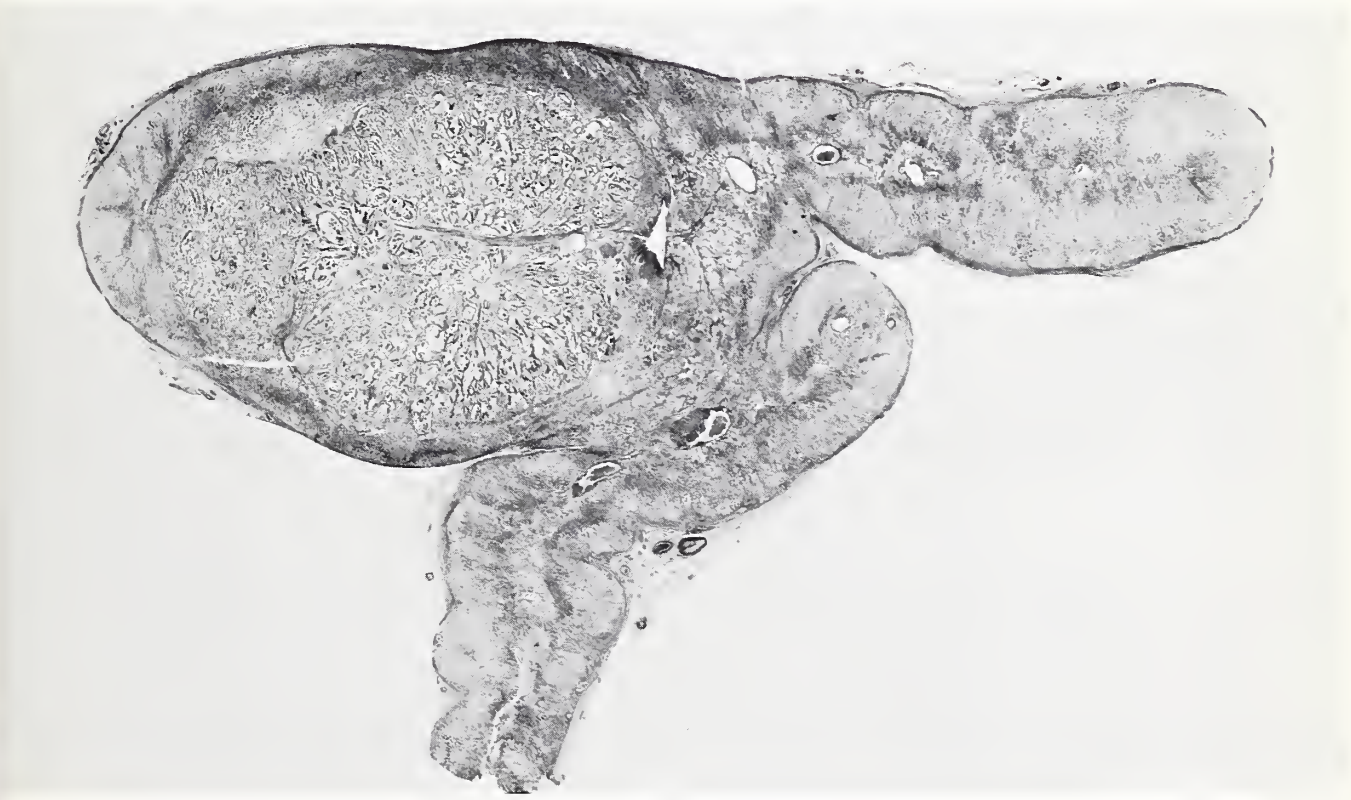

Figure 45. Photomicrograph of adenocarcinoma, metastatic from bronchogenic carcinoma. Nodule principally in medulla. × 6. See figure 46. A. F. I. P. Neg. Acc. No. 218755–40.

Figure 46. Photomicrograph of adenocarcinoma, metastatic from bronchogenic carcinoma. Same case as figure 45. Nodules appear to have extended from medulla into cortex. Compression of cortical tissue around nodules. × 150. A. F. I. P. Neg. Acc. No. 218755–41.

Figure 47. Photomicrograph of spindle cell sarcoma, metastatic from finger. Note situation in medulla and compression of surrounding tissue. × 20. A. F. I. P. Neg. Acc. No. 218755–42.

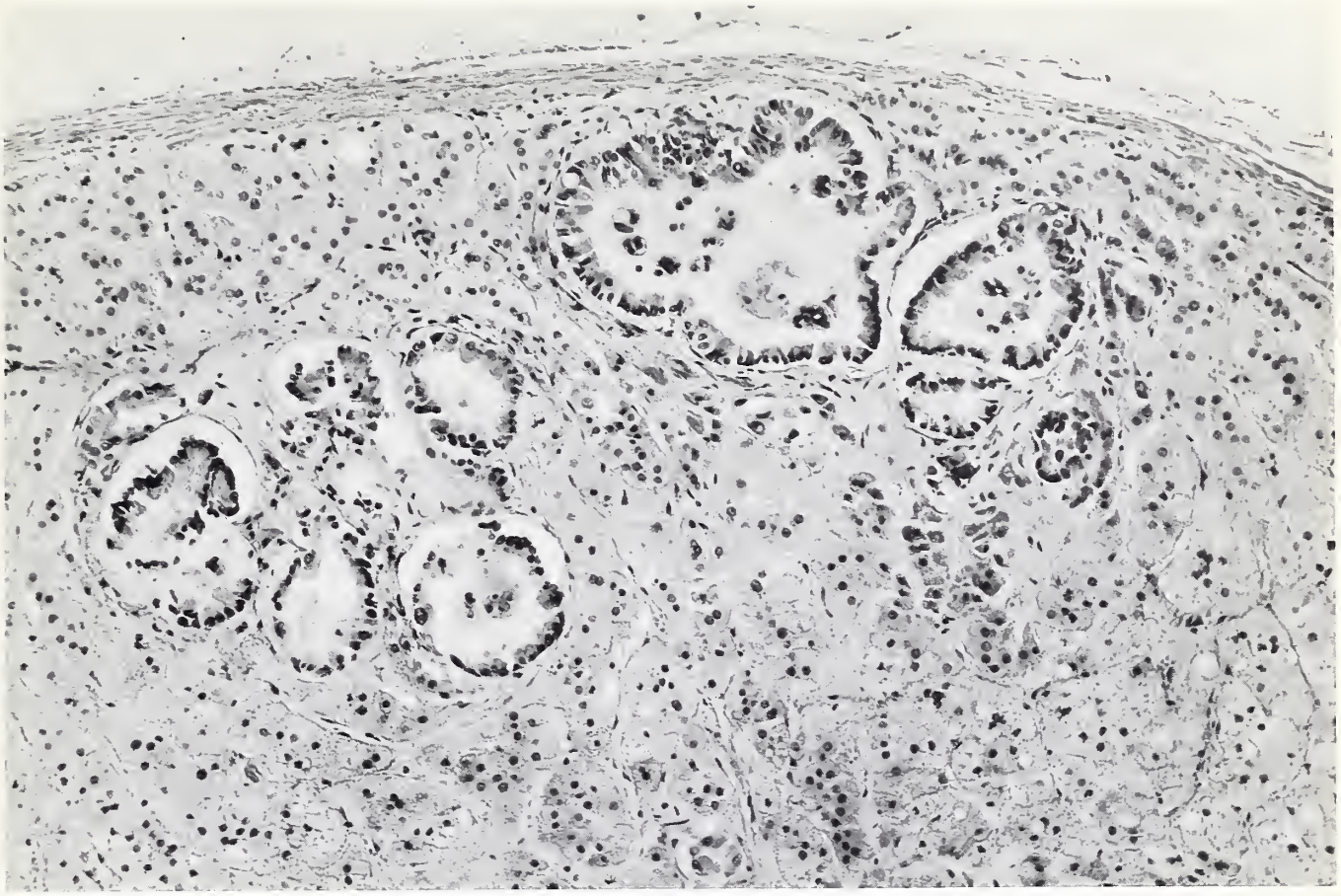

Fig. 46

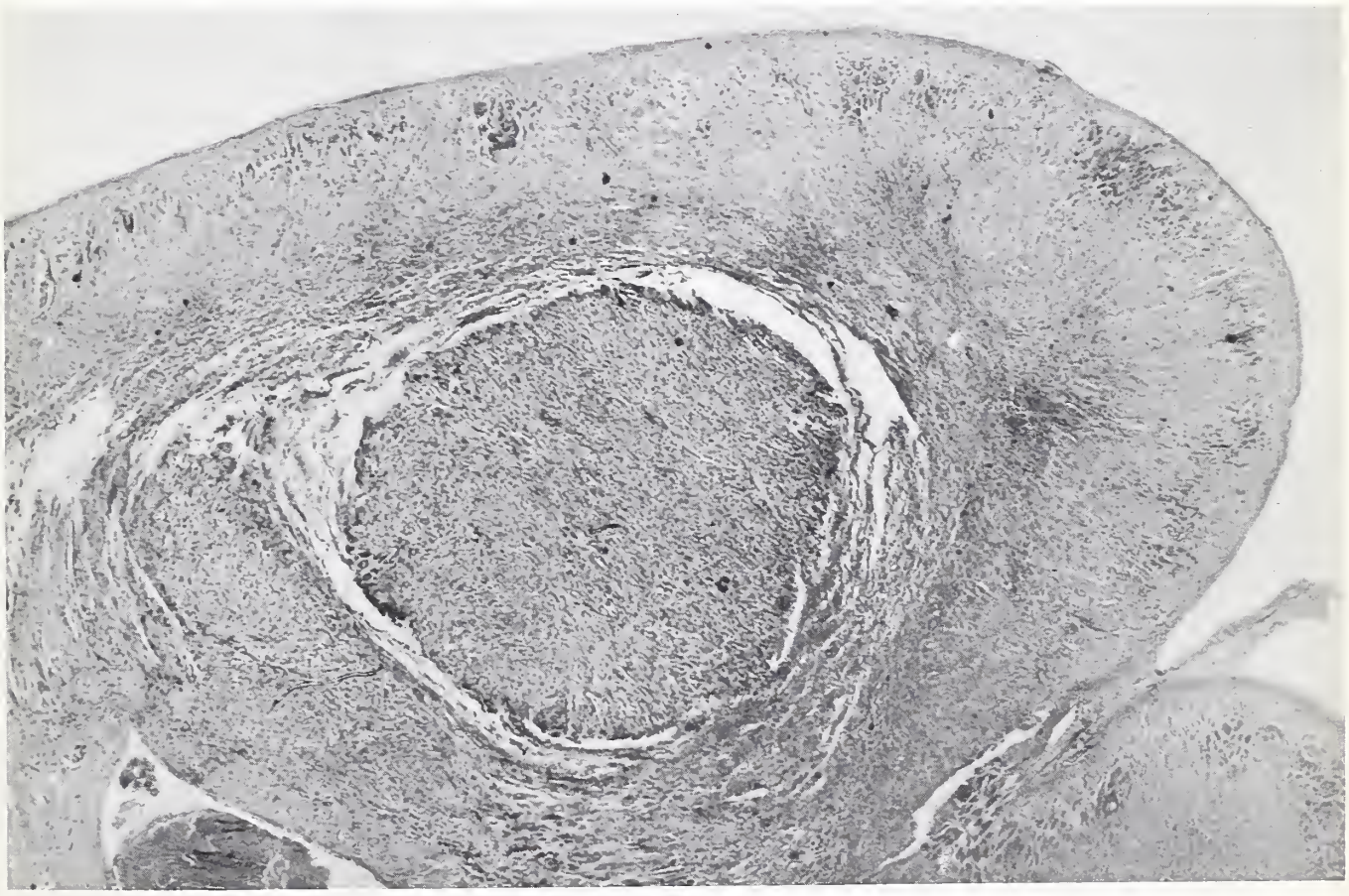

Fig. 47

MELANOMA
AND
SECONDARY TUMORS
PROFESSIONAL NOTES AND FINDINGS

SECONDARY TUMORS

DIRECT EXTENSION. This may take place from neoplasms of the kidney, carcinoma of the pancreas, stomach and esophagus, and from metastases in neighboring retroperitoneal lymph nodes (Willis). Of 149 cases of secondary malignant tumor in the adrenal, we have observed direct extension only twice; namely, from a renal carcinoma and from an embryoma of the kidney.

LYMPHATIC PERMEATION. This is rare, but is reported in widespread carcinomatosis.

RETROGRADE VENOUS EXTENSION. This rare occurrence has been reported in a tumor invading the inferior vena cava and extending into the adrenal vein and to the adrenal.

METASTASIS. This is almost entirely by blood vascular transmission of neoplastic emboli. Although the rich vascularity of the cortex suggests that emboli should lodge there, Willis reports that when the site of early growth in the adrenal can be identified, it is in the medulla (figs. 45, 47). Only rarely is it in the cortex or cortical nodules. Burke reports that in 48 cases metastases were in the medulla in 27, in both medulla and cortex in 19, and in the cortex alone in only 2.

In an analysis of the reports of 1,063 autopsied cases of carcinoma, adrenal metastasis was found in 124 or 11.8 percent. They are more often bilateral and multiple than single or unilateral. From a review of 116 cases of metastasis to the adrenal, Willis reports that 89 were multiple and bilateral, 7 were multiple and unilateral, and 20 were solitary (figs. 43, 46). We found 20 bilateral in 39 cases. Thus, about 50 to 75 percent are bilateral. Of unilateral metastases, Willis states that there is a slight preponderance in the right adrenal, which he attributes to the larger size. Of our 19 cases, 11 were in the left and 8 in the right adrenal.

The combined figures from Willis, Burke, and my own data give the source of the primary carcinoma in descending order of frequency as mammary gland, stomach, colon, lung, biliary passages and kidney. The incidence of metastases is conditioned by the incidence of the primary tumor, by widespread or selective metastases, by anatomical relations, and by unknown factors. However, the primary may be in practically any place in the body. Bronchogenic carcinoma metastasizes to the adrenal in from 20 to 30 percent of cases, and Willis postulates a special condition in the adrenal favorable to the growth of emboli from the pulmonary tumor. Burke states that the adrenals may be affected in cases

of bronchogenic carcinoma when other metastases are scanty or even absent, whereas adrenal metastases from other sources, although frequent, are associated with a widespread dissemination of carcinoma.

Other malignant tumors may metastasize to adrenals: for example, sarcomas of other sites and origins, melanomas of the skin and eye, or tumors of the opposite adrenal, such as sympathicogonioma.

The adrenals may be involved in any of the forms of Hodgkin's disease, lymphosarcoma, reticulum cell sarcoma, and lymphomas, and may also be involved in lymphoid leukemia. Both adrenals are likely to be affected and may be largely destroyed. Some look on this as due to metastasis, but we hold the view that these are system diseases of the hematopoietic tissues; and since the adrenals may contain heterotopic elements of that system, they may correspondingly take part in the general disease.

The smaller metastatic nodules are generally spherical, fairly well defined, and cause slight compression of the surrounding substance of the adrenal. When there are several metastases in an adrenal, they may vary considerably in size. Secondary tumors may attain great size, up to about 300 grams, in which instance the masses may be irregular in outline or conform roughly to that of the adrenal. Direct extension beyond the confines of the adrenal may take place. As with metastases in general, the degree of differentiation is usually but not invariably that of the primary tumor.

The clinical manifestations are those of the tumor or system disease. Phenomena directly related to the adrenal are rare. However, as in the case reported by Madeheim, there may be adrenal insufficiency and Addison's disease.

References

Burke, E. M. Tumors of the adrenals. Am. J. Cancer, 20: 338–351, 1934.

Madeheim, H. Uber seltene Organcarcinosen bei Magenkrebs. Frankf. Ztschr. f. Path., 55: 447–466, 1941.

Willis, R. A. The Spread of Tumours in the Human Body. London: J. & A. Churchill, 1934.

Army - AFIP - Washington, D. C.

PROFESSIONAL NOTES AND FINDINGS

Library
National Institutes of Health
Bethesda 14, Maryland

DATE DUE

NIHLB	SEP 15 1969		
		MAR 20 1970	
	MAR 18 1977		

NIH LIBRARY
3 1496 00198 2498